

Date: 1.10.2022; 1401/07/09

Patient's Name: S.G

Responsible Physician: Dr.Elahi

Patient presentation: A 45 year-old woman with left breast mass and positive family history (2nd degree)

CC: Left breast mass in UIQ

PE: Left breast UIQ, 3*4 cm, 3 o'clock, 2*1 cm (multicentric)

CNBx: IDC, Grade: 2, ER: 40%, PR: 50%, HER-2: negative, Ki67: 10%, Left axillary Lymph Node: positive

Mets W/U:

CT scan: Osteolytic lesion in right acetabulum. L4 and left acetabulum sclerotic lesion

Bone scan: Metastasis in right acetabulum.

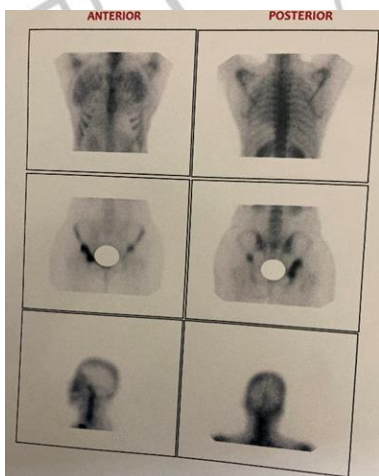
Question:

What are the bone lesions?

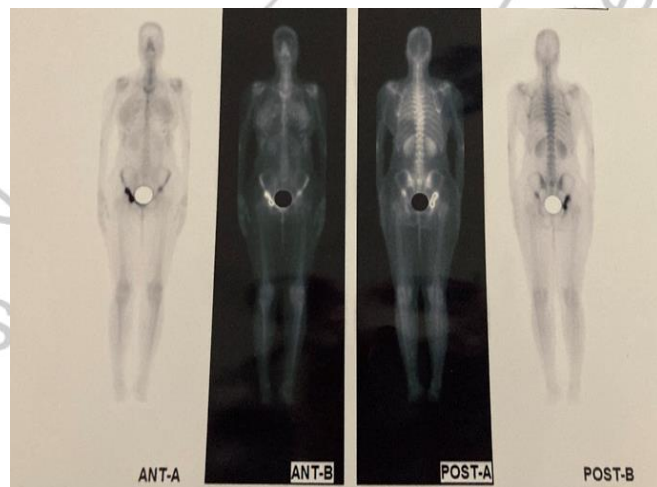
What is the treatment plan?

Recommended plan:

PET scan



1: Bone scan



2: Bone scan