

Date: 11.03.2023; 1401/12/20

Patient's Name: M.I

Responsible Physician: Dr.Moosavi

Patient presentation: A 70 year-old woman with right breast cancer and positive axillary lymph node, underwent neoadjuvant chemotherapy (NAC) and Breast-Conserving Surgery (BCS) and axillary lymph node dissection (ALND). In the preoperational chest CT scan one lesion in left clavicle was seen that has uptake in the bone scan suggested a metastatic lesion, after neoadjuvant chemotherapy NAC in the PET scan this lesion reported as metastatic lesion.

Question:

Is the left clavicle lesion considered as metastases?

Recommended plan:

- 1- After review of imaging the clavicle lesion is considered as metastases and clavicle radiotherapy was recommended.
- 2- In the review one nodule in the lung was seen that is needed to follow up 3 months later.

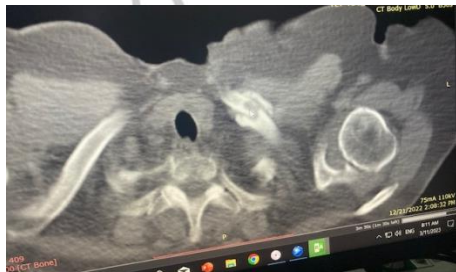

Figure 1: CT scan of chest, left clavicle lesion, before neoadjuvant chemotherapy.

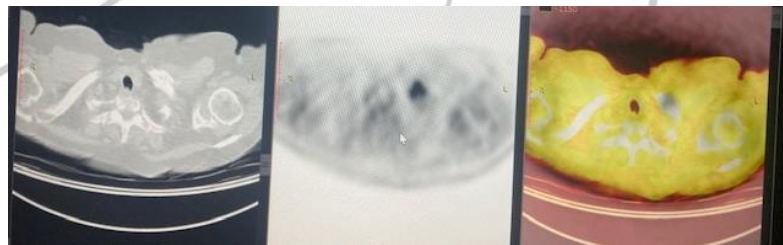


Figure 2: CT scan and PET scan of chest, left clavicle lesion, after neoadjuvant chemotherapy

Most Disease Research