

Date: 04.03.2023; 1401/12/13

Patient's Name: H.RE

Responsible Physician: Dr.Mahmoodzade

Patient presentation: A 62 year-old woman with right inflammatory breast cancer that underwent modified radical mastectomy (MRM) 3 months ago (IDC, TN65%). After 2 months skin lesion (erythematous patch with rapid growth in mastectomy bed) appeared.

Biopsy of skin lesion: skin metastasis is proven.

Question:

1-Is local surgery recommended?

2-Could radiotherapy be helpful?

Recommended plan:

After review of imaging a pathologic mediastinal lymph node was detected in addition to right plural effusion and suspicious metastatic nodule in right lung. Due to extension of skin metastasis, radiotherapy was not recommended and systemic therapy is suggested.

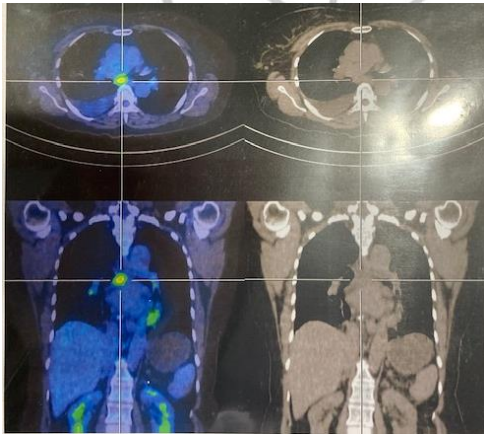


Figure 1: Pathologic mediastinal LAP in PET scan

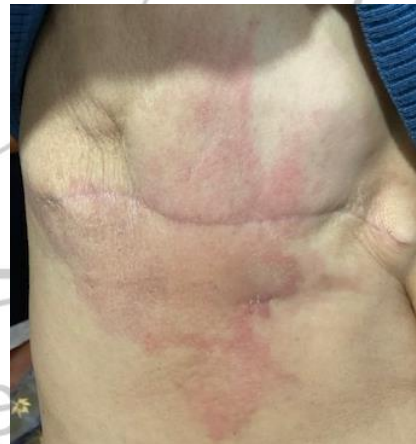

Figure 2: Erythematous patch in mastectomy bed