

Date: 21.01.2023; 1401/11/1

Patient's Name: F.B

Responsible Physician: Dr.Sphandbod

Patient presentation: A 42 year-old woman with history of left breast cancer and she underwent breast-conserving surgery (BCS), adjuvant chemotherapy and radiotherapy 5 years ago. After 4 years she had recurrence and she underwent mastectomy again (IDC). Adjuvant chemotherapy was done, after 6 months a 3*2cm ulcer appeared in the bed of mastectomy (biopsy proved recurrence), PET scan was done, in addition to lesion in the mastectomy bed, there is an increased uptake in the front side of axillary.

P/H: Right breast and axilla were normal.

Question:

What is the next plan?

Recommended plan:

- 1-Core needle biopsy from suspicious right axillary node and IHC.
- 2-MRI of breast.

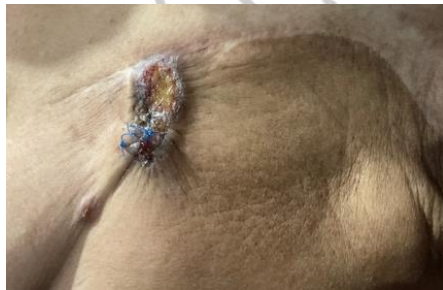

Figure 1: Ulcer in the mastectomy bed

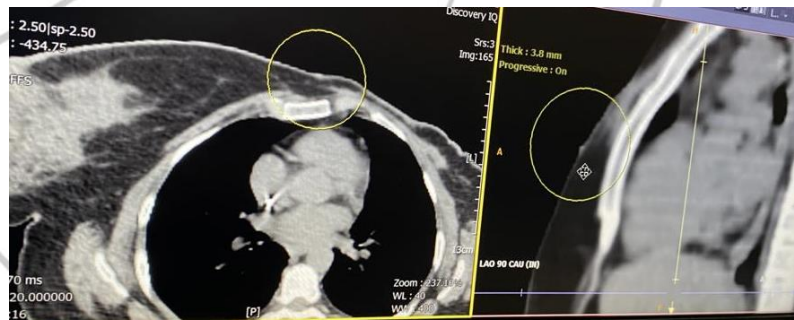


Figure 2: Skin nodule

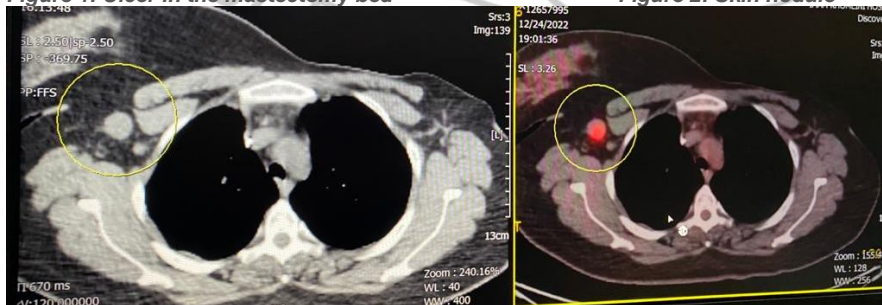


Figure 3: Contralateral suspicious lymphadenopathy

مرکز تحقیقات بیماریهای پستان

