

Date: 21.01.2023; 1401/11/1

Patient's Name: M.M

Responsible Physician: Dr. Shahi

Patient presentation: A 63 year-old woman with history of left breast cancer 2 years ago and she underwent Modified Radical Mastectomy (ILC, Luminal type), neoadjuvant chemotherapy, radiotherapy and Letrozol intake.

At the follow up CA125 63 units/ml rise was seen.

PET scan: increased uptake in the mastectomy bed was reported that this lesion in the CT scan reported as a collection, this time she received radiotherapy 1 session.

Question:

What is the treatment plan?

Recommended plan:

- 1-Stop radiotherapy
- 2-Target sonography from mastectomy bed
- 3-Wire localization and excision of suspected lesion.

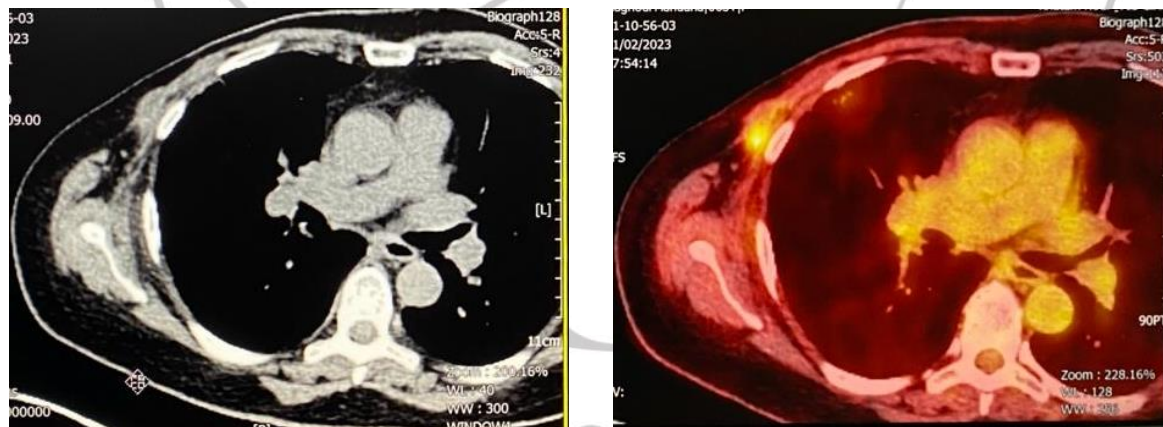


Figure 1, 2, increased uptake in the mastectomy bed.