

Date: 19.10.2024; 1403/07/28

Patient's Name: M.K

Responsible Physician: Dr.Esfandbod

Patient presentation: A 56-year-old woman with a group of microcalcification in UOQ of right breast so VAB was done for her.

VAB: IDC, ER: positive, PR: positive, HER-2: negative, Ki67:15%.

She underwent NAC sparing mastectomy & SLNB.

The final pathology was: DCIS (5mm) & normal lymph nodes.

21-gene oncotype:

Recurrence Score: 21.

Question:

What is the next treatment plan? Endocrine therapy, Chemotherapy or Radiotherapy?

Recommended plan:

- Endocrine therapy (Letrozole).

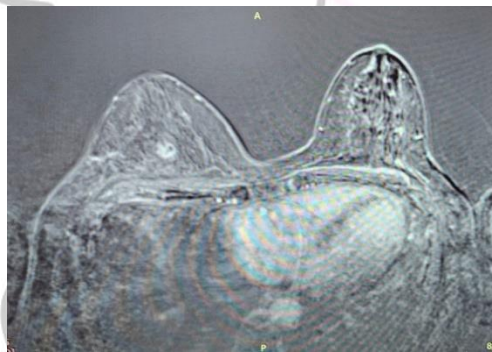


Figure 1: MRI shows the mass in the center of the breast.