

Date: 23.10.2021; 1400.08.01

Patient's Name: O.M

Responsible Physician: Dr.Roodini

Patient presentation: A 46 year-old woman known case of desmoid tumor of right chest wall that underwent resection (removal of right rib, right clavicle & partial pneumonectomy) & radiotherapy in 1376.

Presented with right breast mass in 1400/3/

Sonography: in retromammary of right breast hypoechoic mass 10× 50 mm with irregular margin & 17× 8 mm subareolar mass with microcalcification in left breast.

Mamography: some opacities in left breast

MRI : right sided mastectomy, 3 fat containing lesion in UIQ of left breast

CNB right breast: IDC NOS, G2, ER + 90 %, PR + 20 %, HER2 - , KI67 25 %

CNB left breast: benign fibroepithelial lesion.

CNB of right breast skin lesion: IDC, G1, ER 100%, PR 50%, HER2 -, KI67 15 %

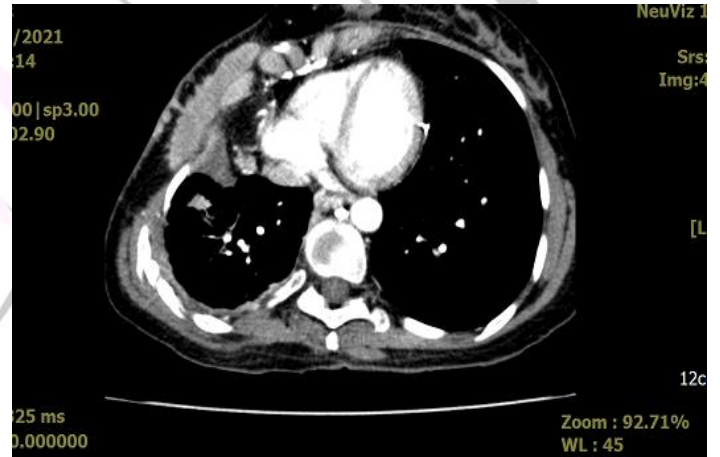
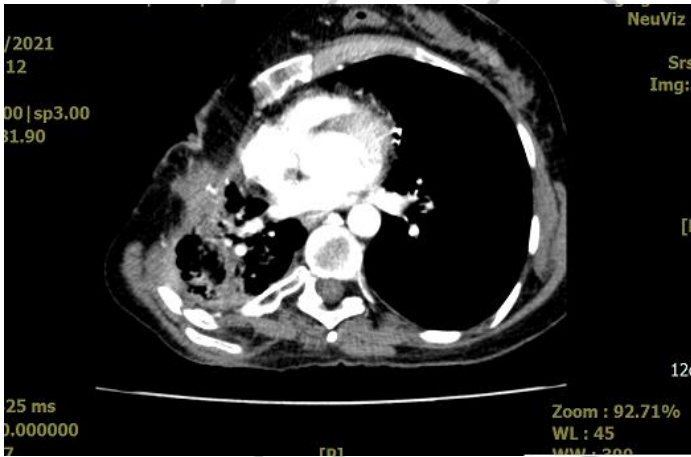
Question:

What's the next plan?

Recommendation:

Because of increased morbidity we recommend systemic therapy.

مركز تحقيقات بيماريهاي پستان



Breast Disease Research Center