

**Date:** 16.10.2021; 1400.07.24

**Patient's Name:** M.D

**Responsible Physician:** Dr.Alipour

**Patient presentation:** A 36 year-old woman with breast mass inferior of areole (3 cm)

CNB: IDC ER 60 % PR 10 % HER negative Ki 67 10 % G1 mucinous component

MRI: Right breast mass fibroadenoma B4 & Left breast mass 3 cm with enhancement

**Question:**

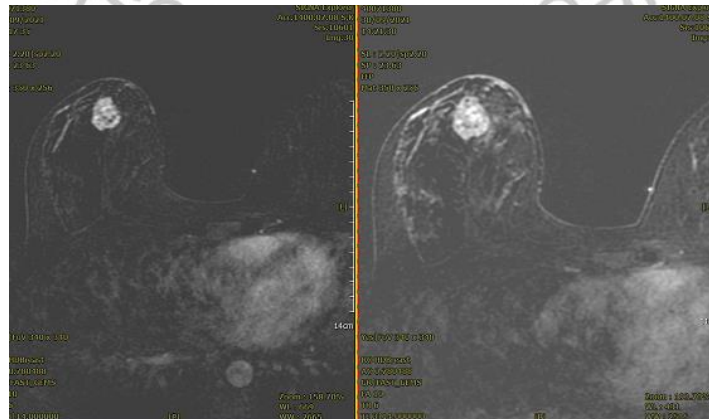
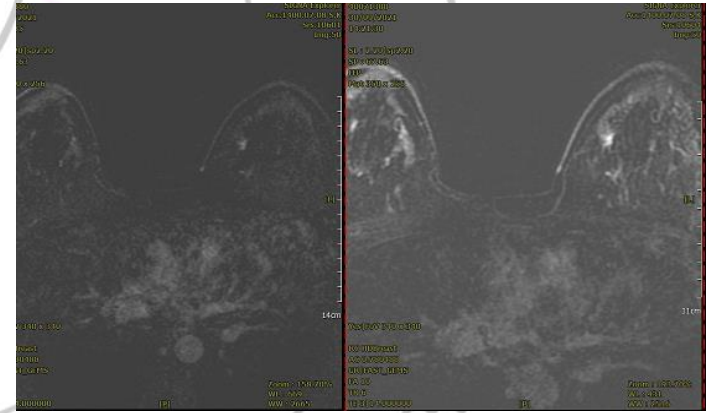
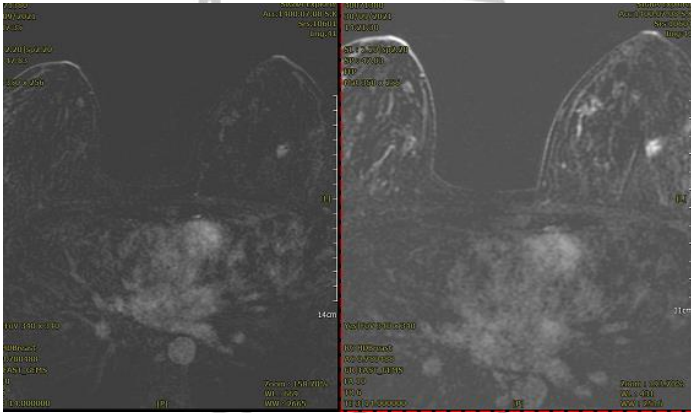
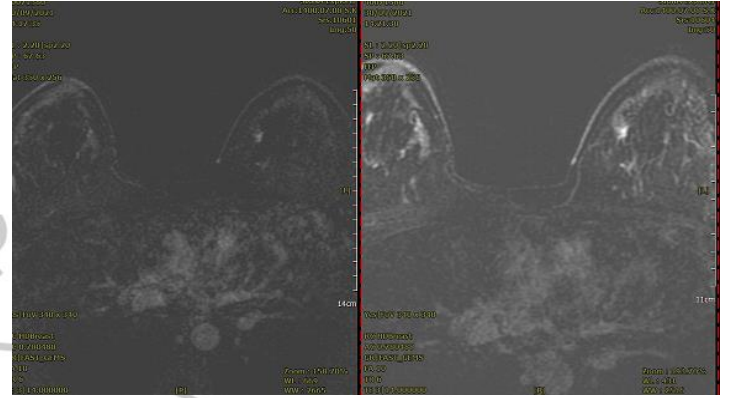
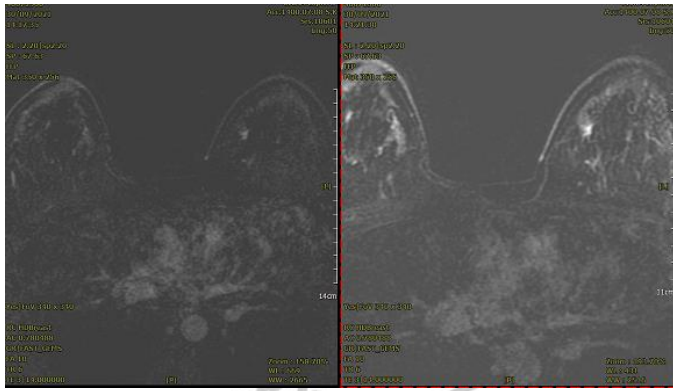
What is the next plan?

**Recommendation:**

Target sonography of left breast.

Prophylactic left breast mastectomy.

Breast Disease Research Center



East Dis... Research Ce