

Date: 16.10.2021; 1400.07.24

Patient's Name: R.A

Responsible Physician: Dr.Alipour

Patient presentation: A 56 year-old woman

Sonography: mass + cyst

US guided biopsy: papillary lesion

Lesion excised: DCIS reported

Pathology reviewed: one focus of ADH & intraductal papillomatosis, LIN 1, LIN 2

MRI: post-operative changes

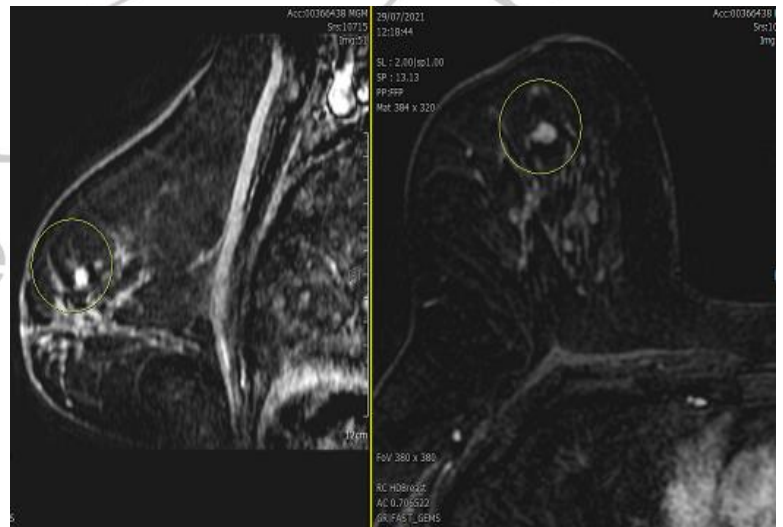
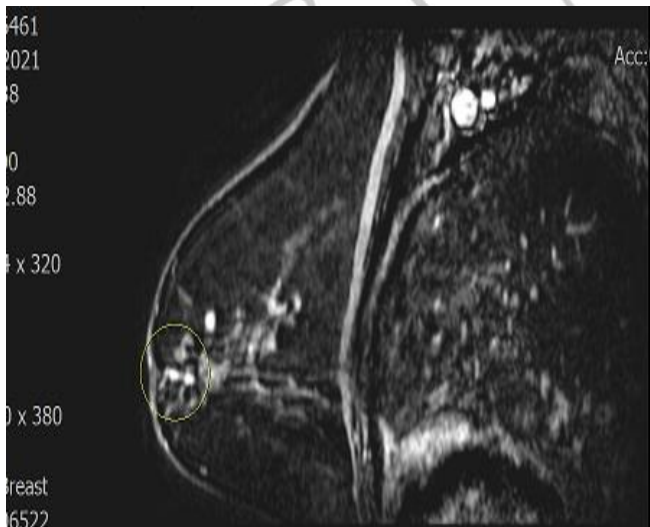
Target sonography & biopsy were done: papilloma & low grade DCIS & foci of LCIS

Question:

What is the next plan?

Recommendation:

BCS



مرکز تحقیقات بیماریهای پستان



Breast Disease Research Center