

Date: 02.10.2021; 1400.07.10

Patient's Name: F.H

Responsible Physician: Dr.Esfandbod

Patient presentation: A 35 year-old woman with left breast mass underwent lumpectomy in 1397.

Pathology:DCIS comedo /cribriform G1 / IDC NOS LVI + , G 1 Margin ?

She underwent reexcision & ALND in 1398.

Pathology: DCIS G3 margin free

Lat. Margin re excision: intramamary LN affected by IDC with ENE /another intramamary LN with invasive component without ENE / IDC G3 LVI + & ALND: 5/10 + ER - , PR - , Ki 67 15 % , HER 3+

She underwent chemo and radiotherapy and Herceptin.

In follow up there was a mass in central of left breast

CNB: IDC G3 ER - , PR - , Ki 67 30 % , HER2 3+

PET CT: 10 mm hypermetabolic left interpectoral metastatic lymphadenopathy

She underwent MRM

Pathology: IDC comedo G2 / 5x 4 x 3, LVI + , all margins are free

Question:

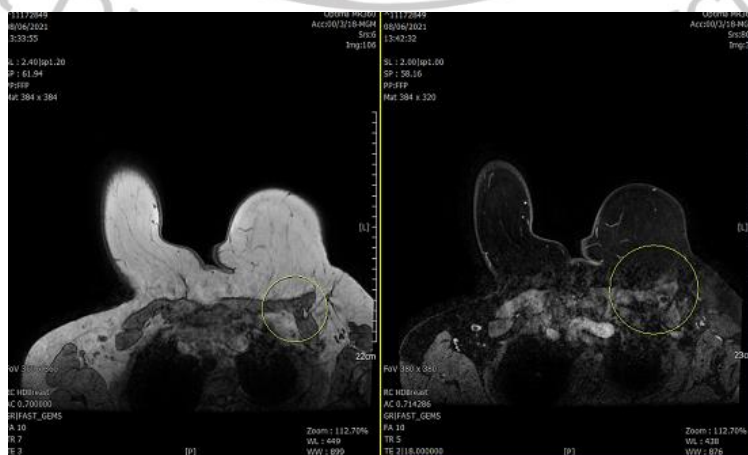
What's the next plan? Surgery or Radiotherapy?

Is it necessary to change to another anti HER-2 drug?

Recommendation:

1-Targeted sonography from the LN seen in PET and if positive for cancer surgery is recommended.

2-Best anti HER-2 is dual blocked by pertozomab+ TDM1 and if not possible use Herceptin.



مرکز تحقیقات بیماریهای پستان



Breast Disease Research Center