

Date: 01.05.2021;1400.02.11

Patient's Name: B.A

Responsible Physician: Dr.Omranipour

Patient presentation: A 39 year-old woman with multicentric right breast cancer and LAP and Ascites.

FH: + (Her mother)

CNB (UOQ,LIQ): IDC, ER+, PR+, HER2 2+, Ki67 35-45%

CISH : negative

Bone Scan: multiple bone metastases

CT: Ascites, Omental seeding, ovarian mass, liver metastasis, pleural effusion, Right hydronephrosis

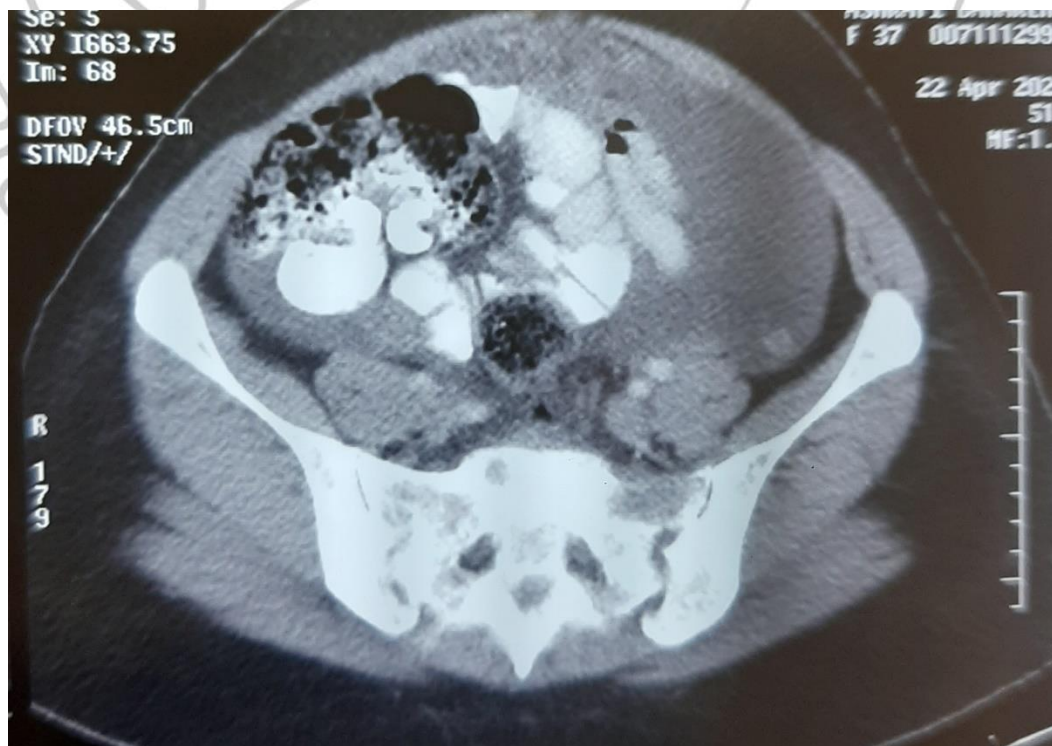
Question:

What's the next plan?

Is she a candidate for Diagnostic Laparoscopy and Bx or oophorectomy before breast treatment?

Recommendation:

- 1.Ascitis cytology and IHC and omental cake Bx.
- 2.Check CEA, CA125, HPE4
- 3.Refferd to oncologist.

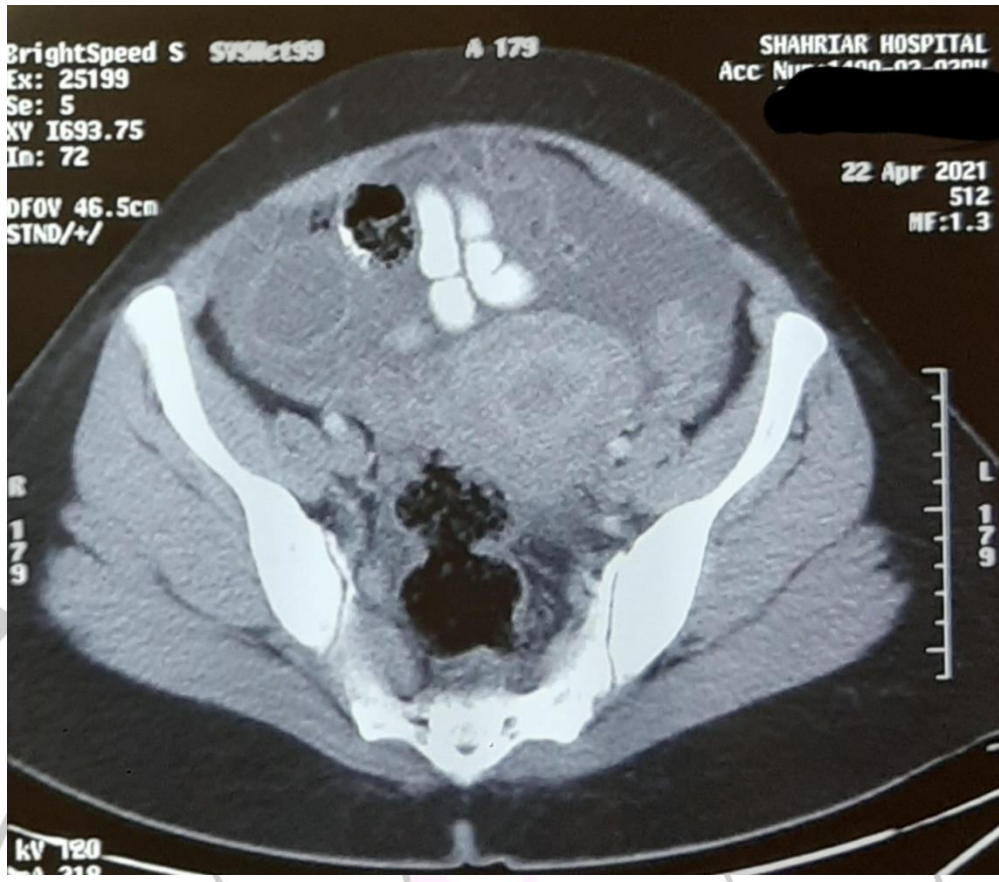


BrightSpeed S SYS#ct99
Ex: 25199
Se: 5
XY I693.75
In: 72

SHAHRIAR HOSPITAL
Acc No: [REDACTED]

22 Apr 2021
512
MF:1.3

DFOV 46.5cm
STND/+/



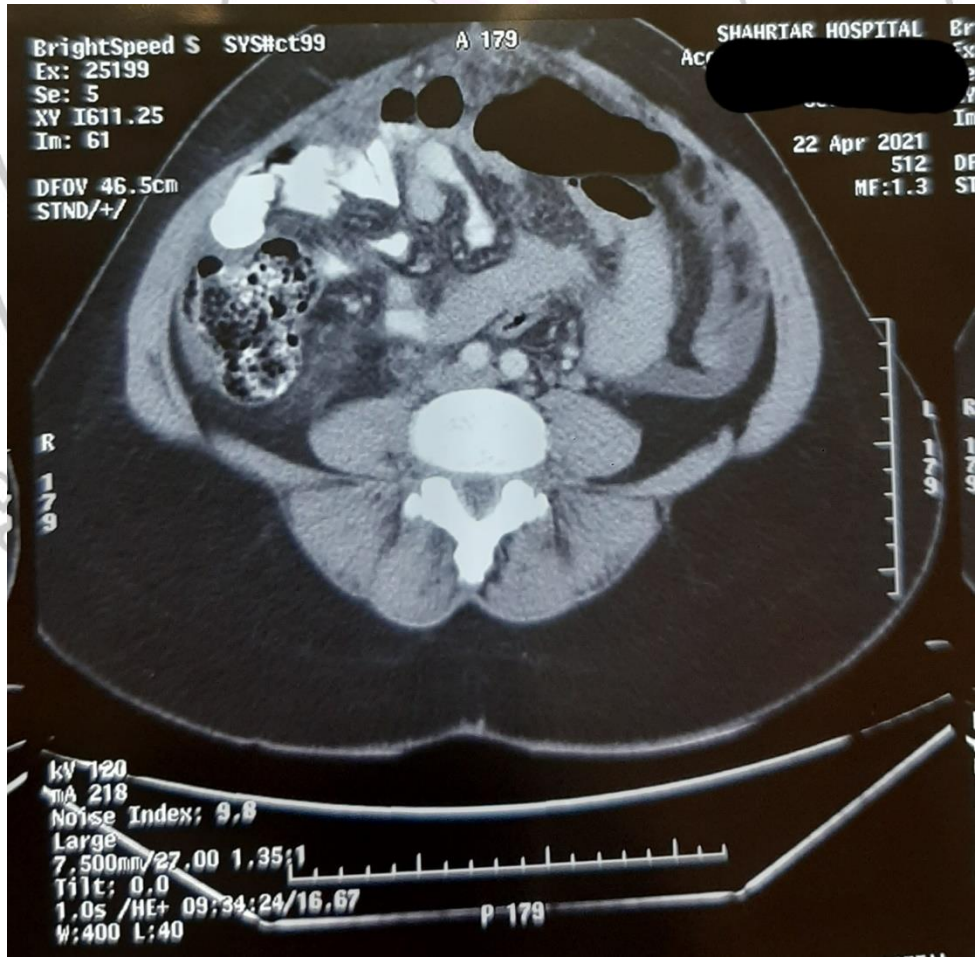
kV 120
mA 218

BrightSpeed S SYS#ct99
Ex: 25199
Se: 5
XY I611.25
Im: 61

SHAHRIAR HOSPITAL
Acc No: [REDACTED]

22 Apr 2021
512
MF:1.3

DFOV 46.5cm
STND/+/



kV 120
mA 218
Noise Index: 9.9
Large 7.500mm/27.00 1.35:1
Tilt: 0.0
1.0s /HE+ 09:34:24/16.67
W:400 L:40

P 179

مرکز تحقیقات بیماریهای پستان



Breast Disease Research Center