

Date: 10.4.2021;1400.1.21

Patient's Name: N.S

Responsible Physician: Dr.Vasigh

Patient presentation: A 31 year- old pregnant woman (1st trimester) with left breast mass

FH: Negative

US: A 9mm hypo echoic left UOQ mass (B4a)

CNBx: DCIS, G2, ER+, PR + (10%), Ki67 5-10%

MG: Bilateral punctate and microcalcification with diffuse distribution (Benign type);

Right Upper Asymmetry

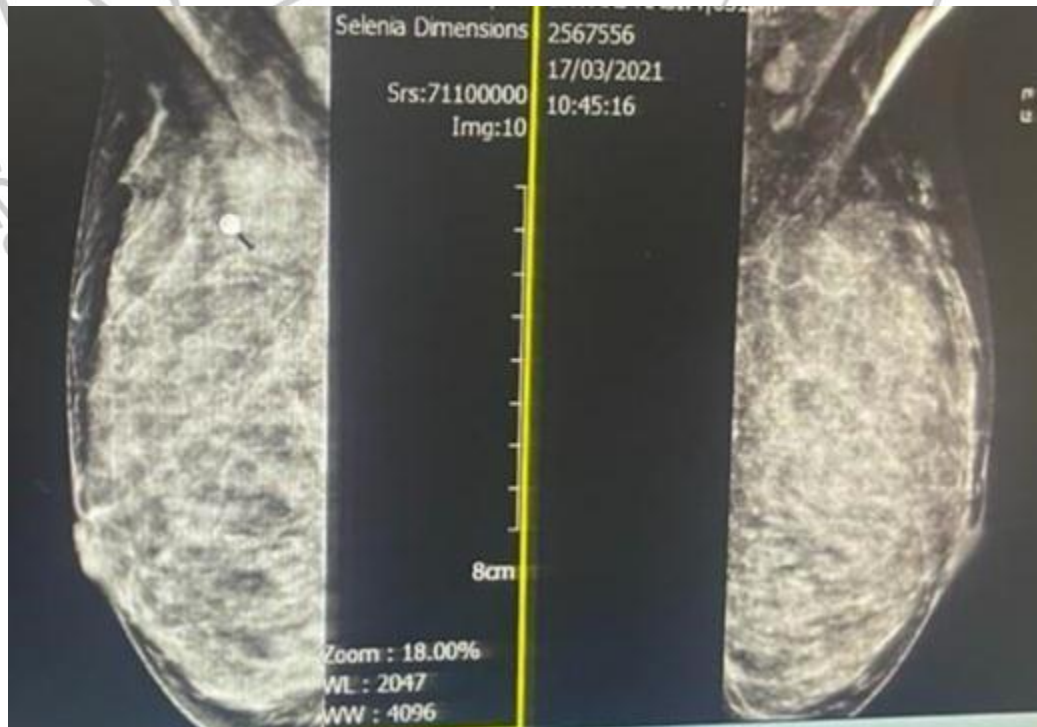
Pathology Review: FCC+UDH

Question:

What's the next plan?

Considered plan:

1.Wire guided excisional Bx



مرکز تحقیقات بیماریهای پستان



Breast Disease Research Center