

Date: 10.4.2021;1400.1.21

Patient's Name: M.Z

Responsible Physician: Dr.Elahi

Patient presentation: A 59 year-old woman with left breast mass who underwent VABx.

FH: positive (her sister and her niece, both of them under 40)

MG: Left LIQ microcalcification (B4)

U/S: an iso Hypo echoic 10*15mm mass in left 6 O'clock (B4c)

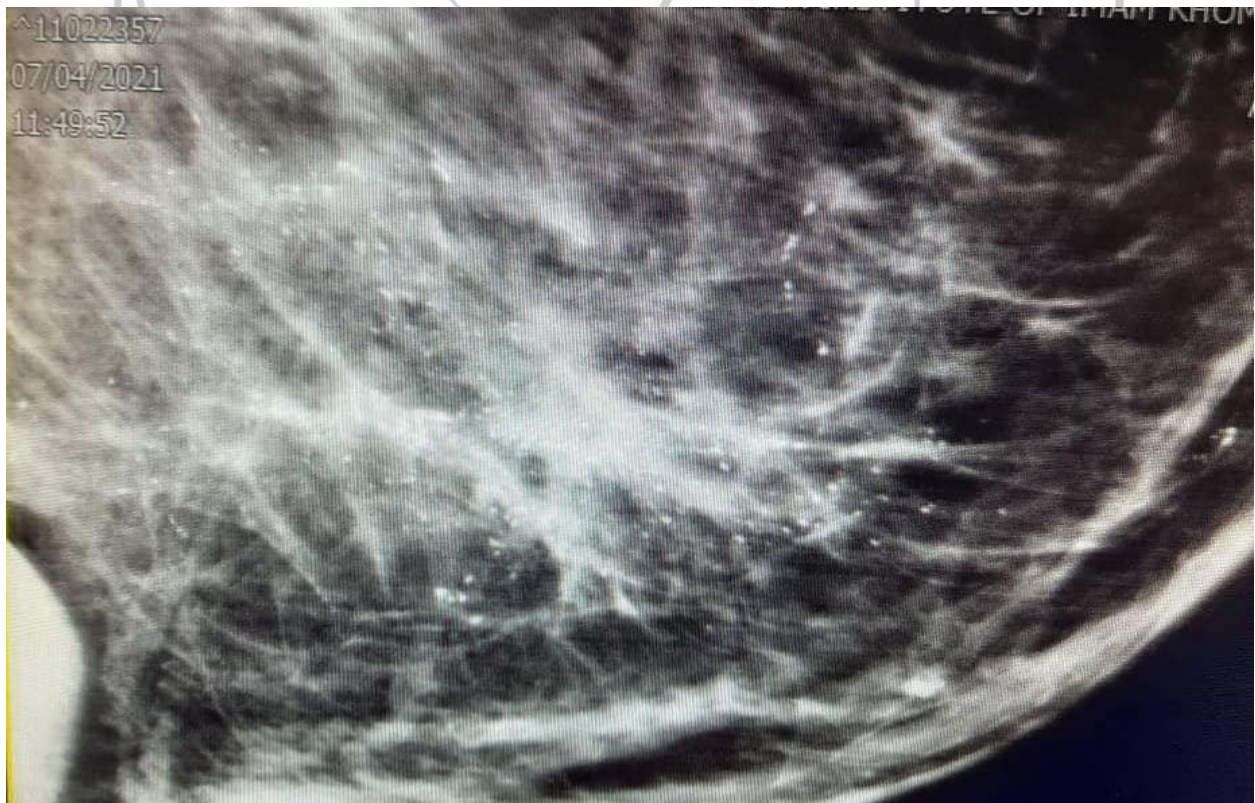
VABx: LCIS, G1, ER+

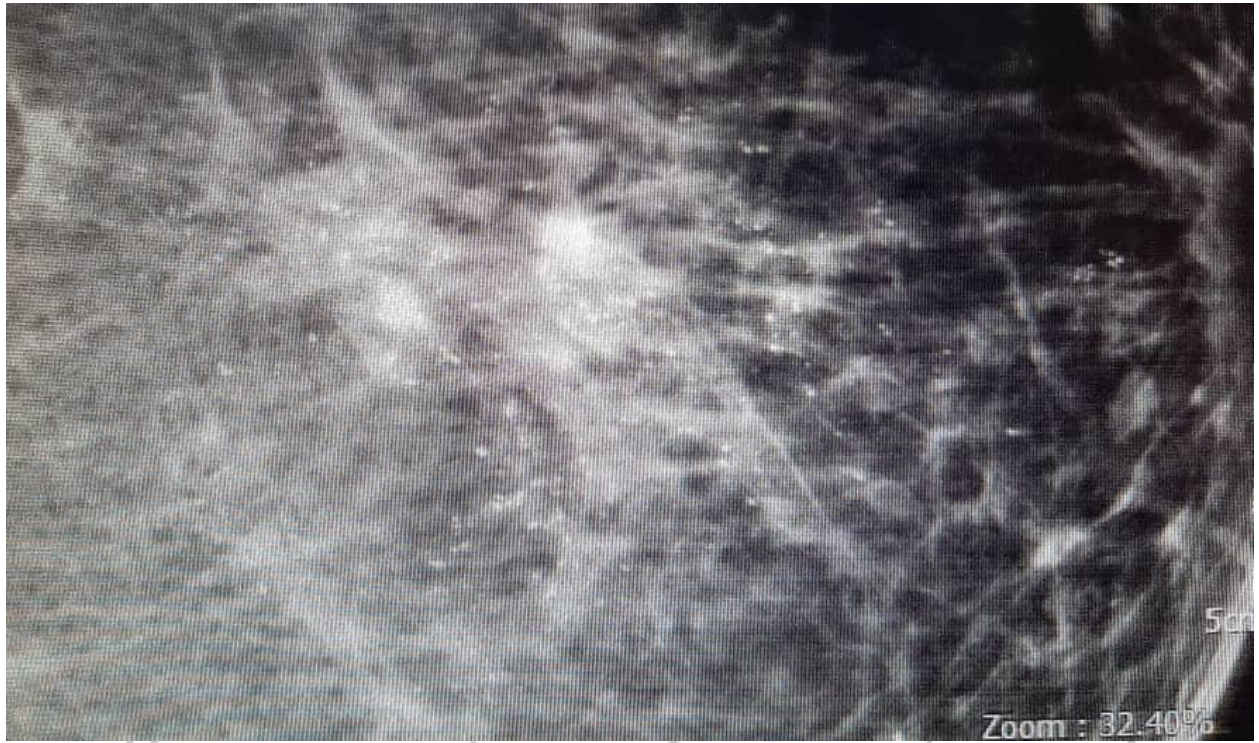
MRI

Question: What is the next plan?

Considered plan:

- 1.Genetic Test is recommended.
- 2 .Left side diffuse microcalcification confirmed in imaging review.
- 3 .Left side prophylactic mastectomy is recommended.





Breast Disease Research Center