

**Date:** 21.11.2020; 1399.9.1

**Patient's Name:** M.R

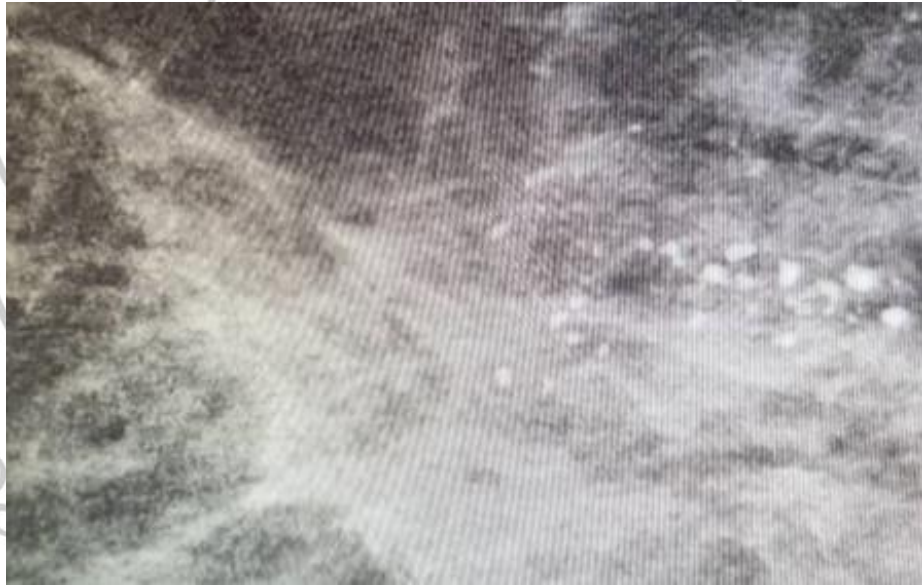
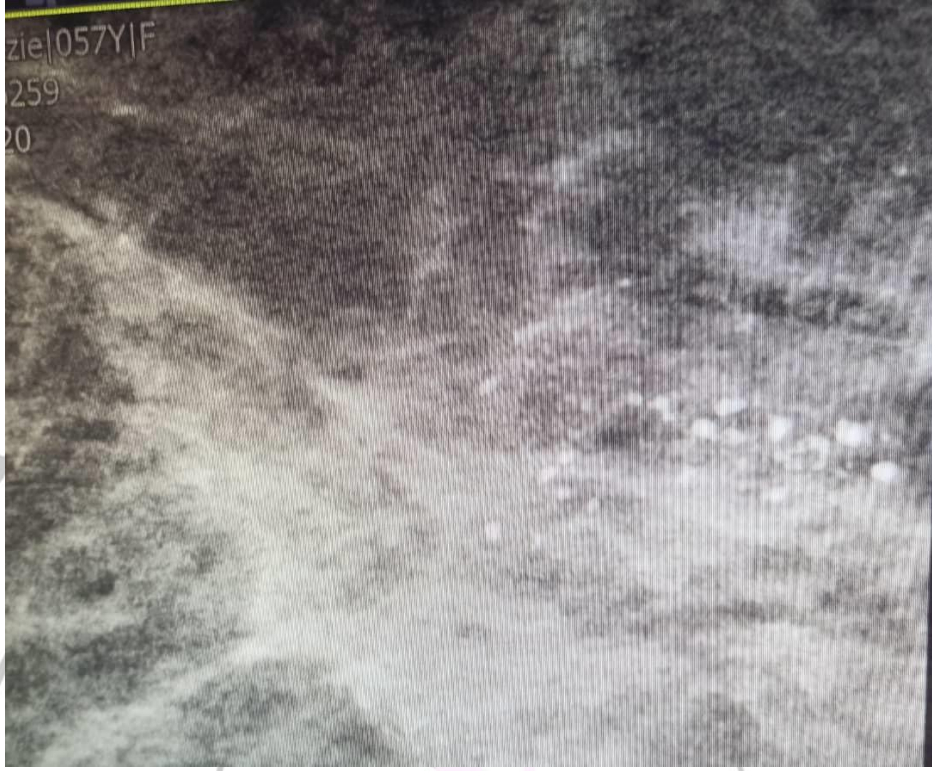**Responsible Physician:** Dr. Elahi

**Patient presentation:**

- 58. yrs. Positive family history of breast cancer in 2 sisters
- In routine screening mammography a group of microcalcification found in UOQ of right breast and assigned as BIRADs 0
- Ultrasound: BIRADs2(some sparse fibrocystics)
- Focal magnification view mammography for further evaluation reported a group of pleomorphic calcifications (BIRADs 4b)
- Vacuum assisted biopsy of a grouped coarse heterogeneous microcalcification done
- Pathology: Fibroadenoma with stromal and glandular calcifications

**Question:** It seems discordant, do we need further evaluation or intervention because of some other microcalcifications seen in mammography?

**Recommendations:** 1- Other few visible calcifications are not suspicious but performing MRI can be more assuring. 2- Genetic counseling has to be done.



پنهان

۱۳۸۵

Breast

Center

Disease Research