

**Date:** 1399.7.12; 3.10.2020

**Patient's Name:** F.B

**Responsible Physician:** Dr. Omranipour

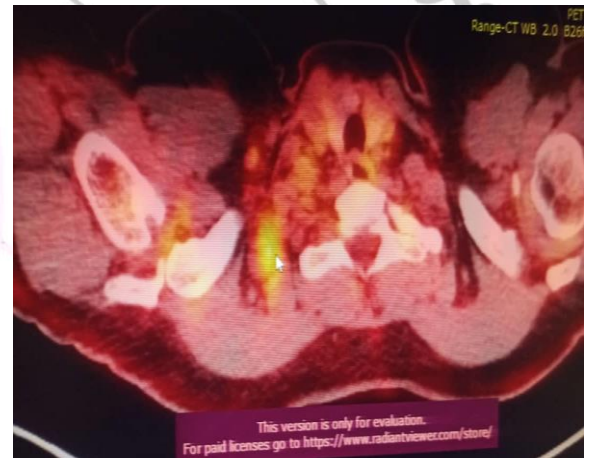
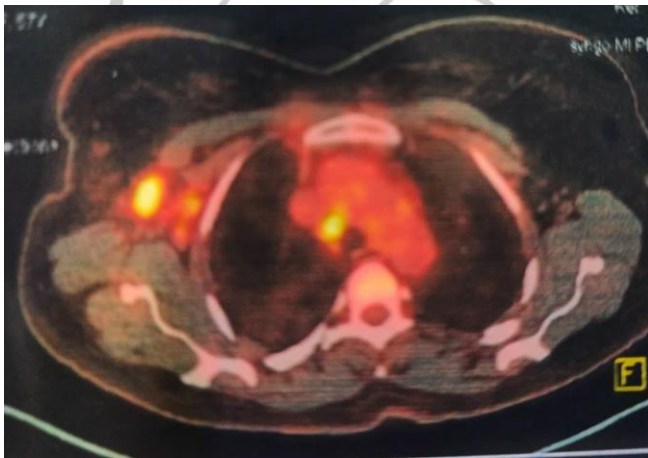
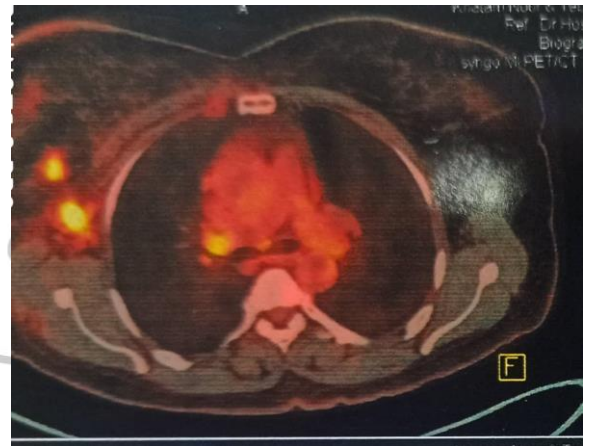
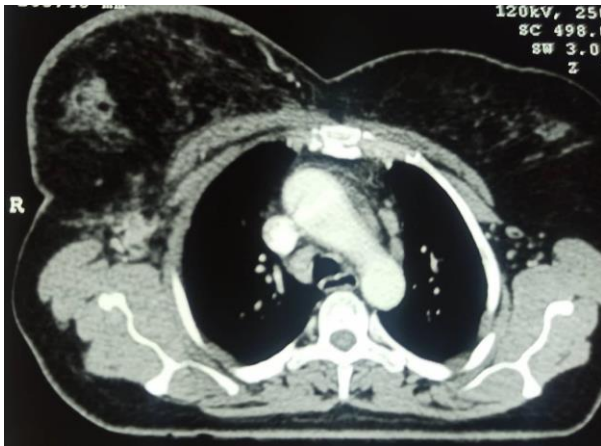
**Patient presentation:**

- 50 yrs
- Large inflammatory mass UOQ of right Br
- CNB: IDC ER+ PR- her2- ki67 35-40% LN+
- Spiral CT scan thoracoabdominolumbar negative but S1 lesion probably hemangioma
- Do perform MRI
- PET scan done: S1 hemangioma and multiple mediastinal & hilar & supraclavicular & neck LNs

**Question:** The next step?

**Recommended work up:** Biopsy of cervical lymph node

Breast Disease Research Center



Breast Disease Research Center