

Date: 1399.7.12; 3.10.2020

Patient's Name: R.H

Responsible Physician: Dr. Vasigh

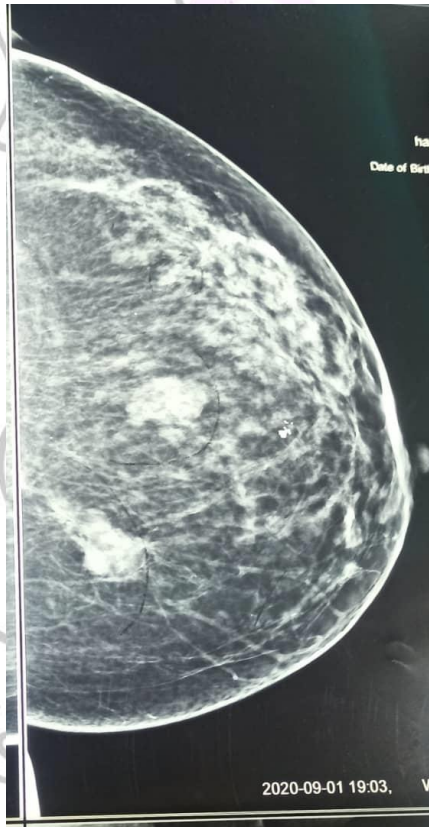
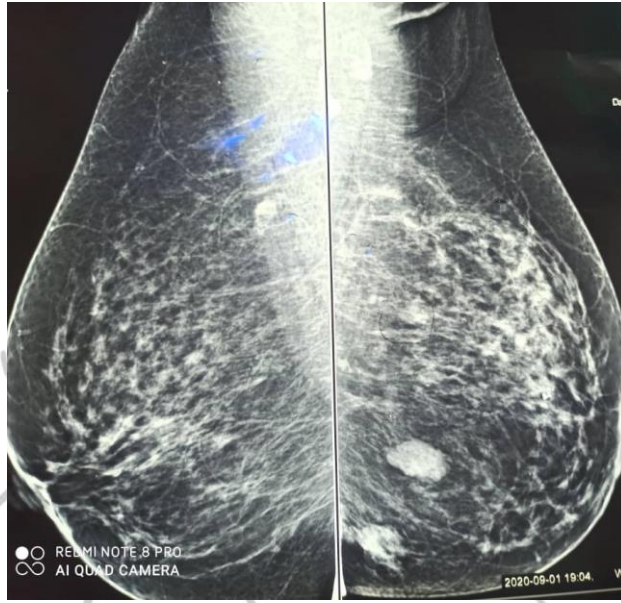
- 44 years , FH + ovarian CA 2nd deg
- According to clinic & paraclinics Pt has multiple masses scattered in different zones of her left Br with these locations and pathologies
- (multicentric suspicious masses in Sono & Mammography)
- Pathology of their CNB
- 7 o'clock farzone IDC mucinous type
- 2 o'clock farzone FCC+ focus of ADH
- 4o'clock midzone PASH (location of the mass in her BSE)

Question: MRM or BCS?

Recommended work up: Nothing

Answer: BCS+ excision of atypia

Breast Disease Research Center



پستان

مرکز تحقیق

Breast Dis

Research Center