

Date: 2020-9-26; 5 -7-1399

Patient's Name: M.R

Responsible Physician: Dr. Omranipour

Patient presentation:

- 53 years
- Left breast cancer (one extensive lesion from 10 to 2 o'clock) IDC -IHC: ER -PR-HER2-, Ki67 20% . Candidate for neoadjuvant chemotherapy
- PET: supraclavicular right LN involved
- Lung Mets- right hilar LN
- MRI without LN enhancement neither hilar nor supraclavicular

Question: PET Review? Does she need lung or LN Bx?

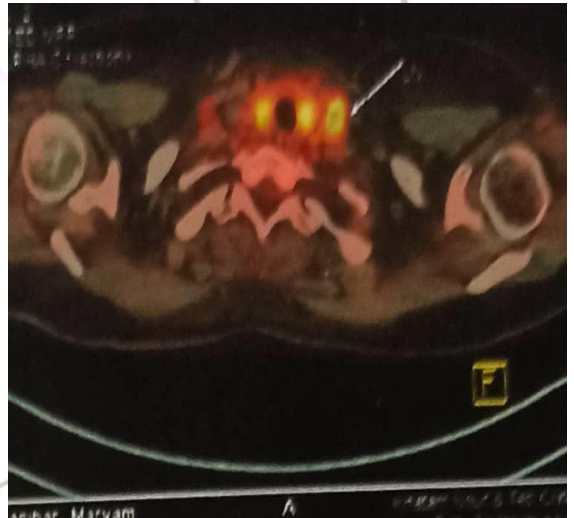
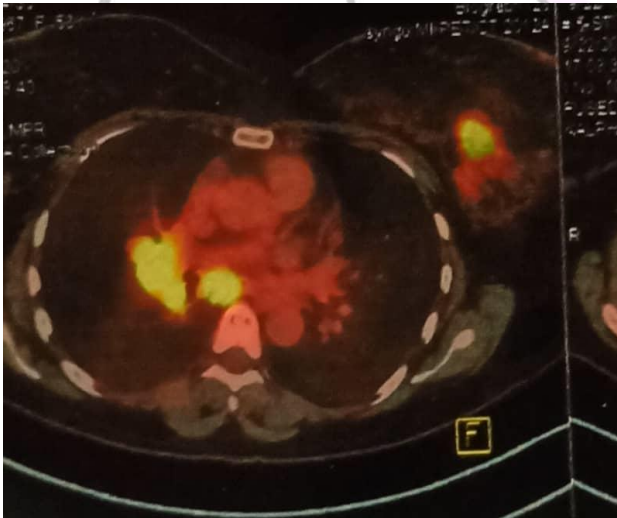
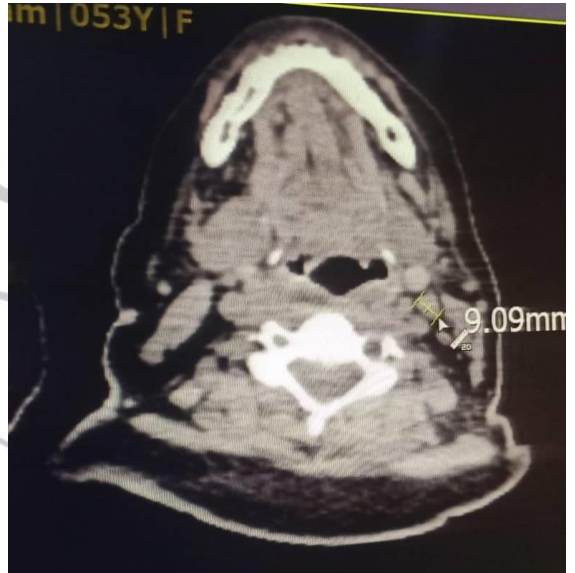
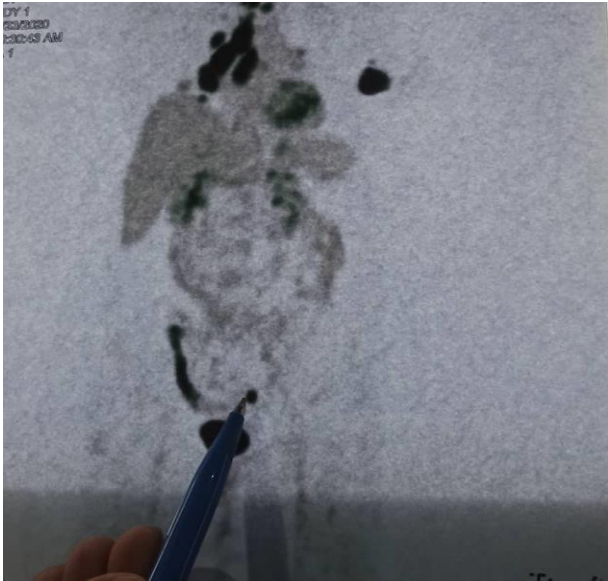
Recommendations: Due to: right hilar LN + in PET

Br LN size 12 mm and lung LN size 14 mm

METS? LYMPHOMA? SARCOIDOSIS? Others?

Also lesion in the sigmoid colon

Recommended plan: Forward to Lung & Supraclavicular Bx & Colonoscopy



East Disease Research Center