Date: 15.05.2021; 1400.02.25

Patient's Name: I.R

Responsible Physician: Dr. Ebrahimi

Patient presentation: A 84 year-old woman with right breast bloody discharge
PEx: thickening in right upper (12-1oclock) & mobile mass in right UOQ & her right nipple is more prominent and stiffer.
PMH: HF(EF 30%) and cardiac pacemaker
DH: Rivaroxaban
US: B0
MG: NL, (Review: multicentric asymmetries and right retro nipple dense mass)

Question:

1.What is next Dx plan?

Recommendation:

1.Target U/S of right breast & US guided Bx is recommended at first.
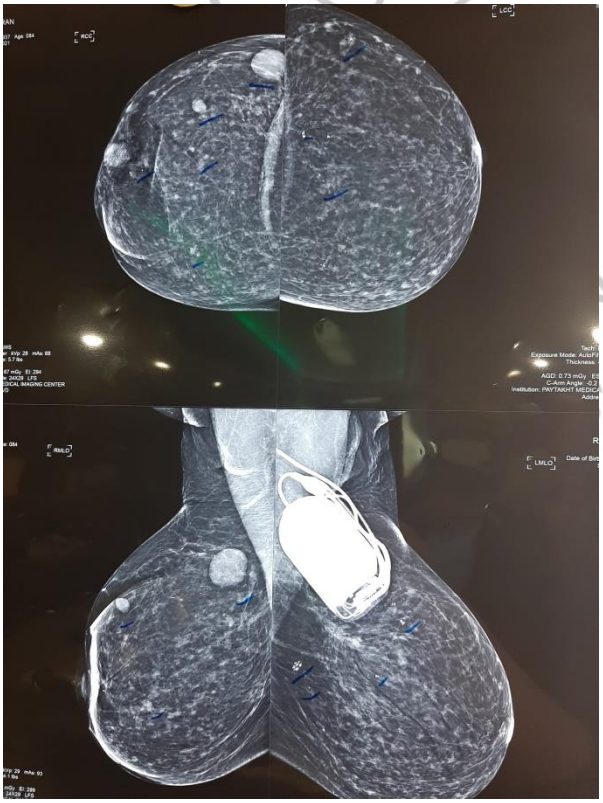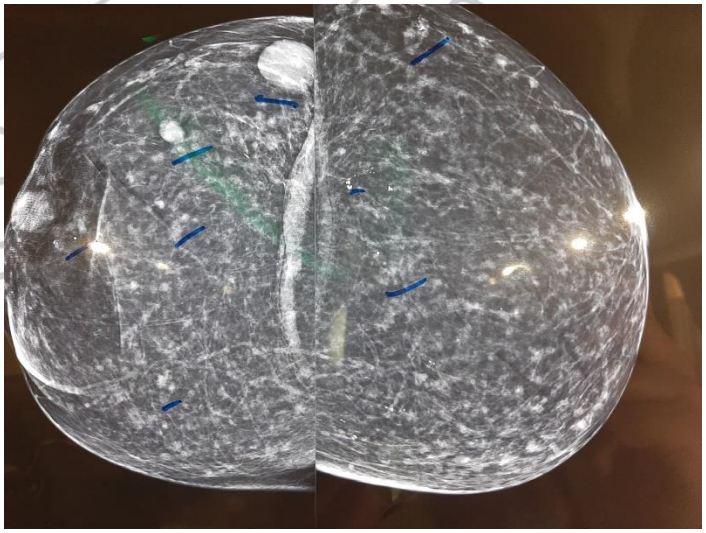
2.Nipple open excisional Bx if guided Bx not feasible.