

Date: 2020/12/26 ;06/10/1399

Patient's Name: N.T

Responsible Physician: Dr. Mohagheghi

Patient presentation:

- 40years – strong positive family history (3 cases 1st & 2nd degree under 40yrs, mother, sister and aunt)

- Presented with Right axillary mass sensation

-12 years ago, bilateral breast augmentation due to hypomastia is done.

- (1/99) Right axillary mass sensation caused decision of prosthesis exchange by the patient.

Sonography: Rupture of right Breast prosthesis piece by piece & multiple collections lateral to breast & air between Breast and axilla. Left Normal retro pectoral Breast prosthesis. Both sides axillary lymph nodes: reactive.

Mammography: evidence of multiple ruptures in retro pectoral prosthesis of right side. BIRADS 0.

(2/99) During surgical exchange of them; * Right capsula & *left capsula & * axillary lymph node &* one incidental peri prosthesis nodule found were sent for pathologic evaluation.

Report: Left side fibrofatty tissue and inflammatory cells

All right-side pathologies: IDC; Grade2; ER+80%; PR +30%; HER2 -; Ki 67 8-10% +; all3 Lymph Nodes involved.

(2/99) Spiral CT scan: small right middle and upper lobe pulmonary nodules -Mild fluid around breast prosthesis at both sides-right axillary lymphadenopathies.

PET scan (2/99) multiple right axillary LNs compatible with metastasis plus diffuse peripheral FDG uptake of the right-side post augmentation which may obscure an underlying malignancy.

She has received 8 courses of neoadjuvant chemotherapy till now and is insisting on preserving both her prostheses and her nipple areola complexes.

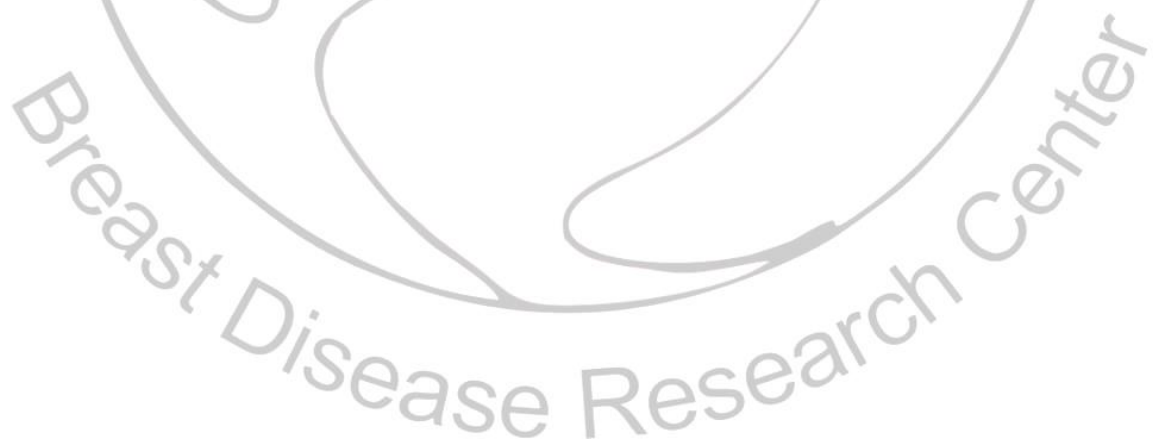On her right breast an incision and a drain lateral to the areola is seen. Her last surgeon explained that each time with extraction of the catheter because of symptomatic seroma accumulation it was inserted once more.

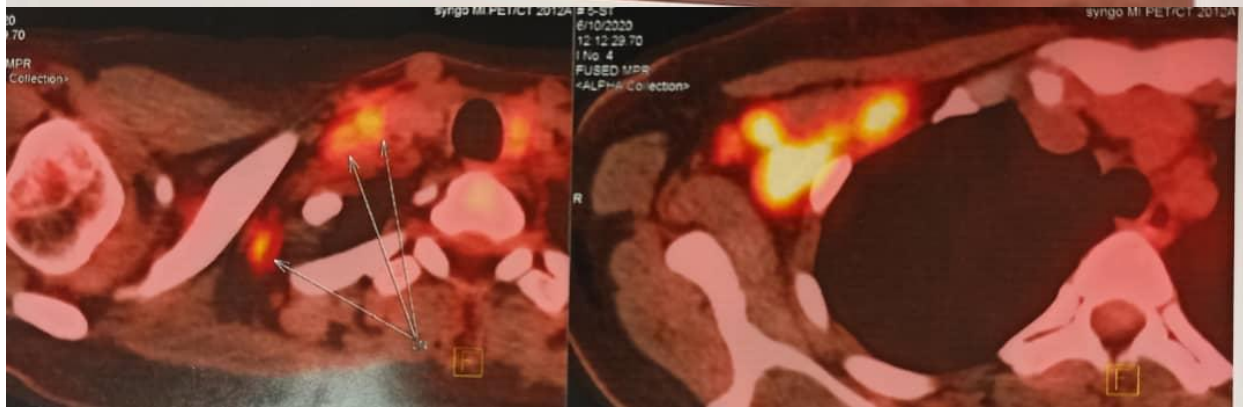
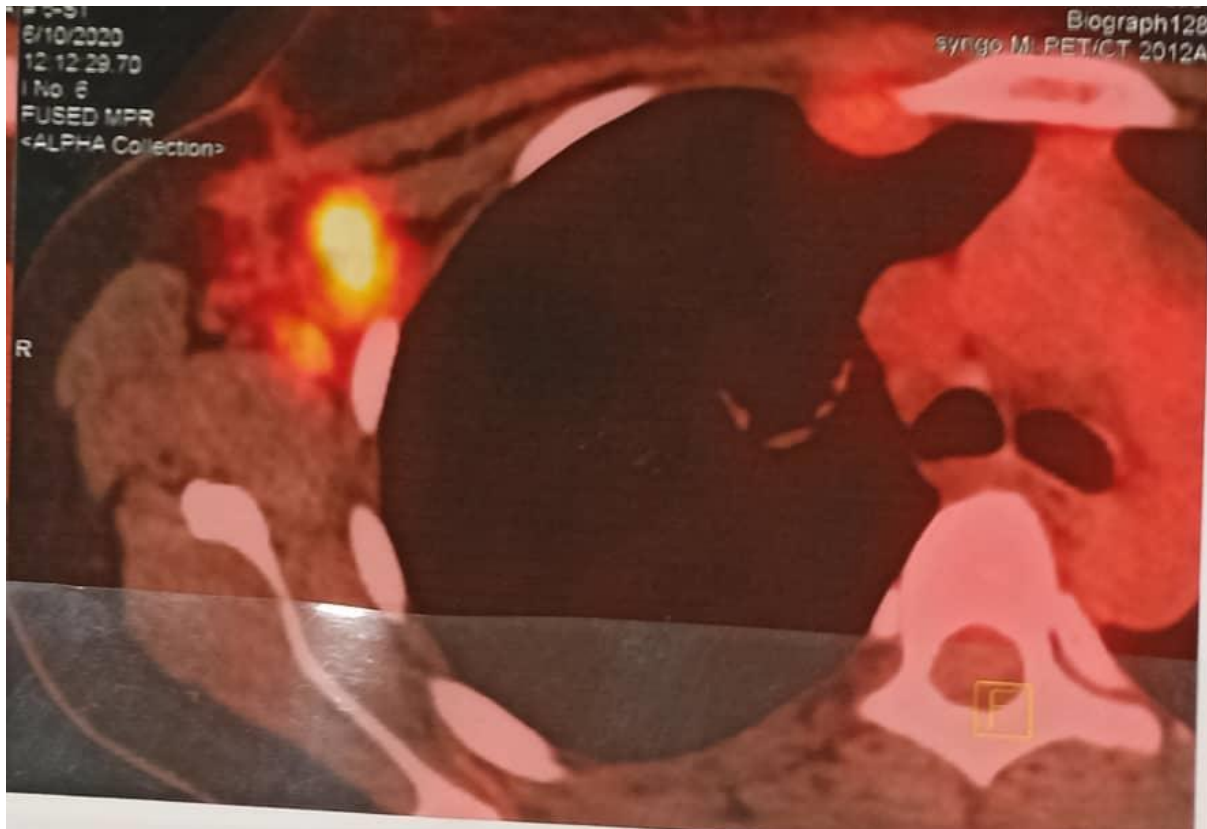-Her oncologist has referred her for surgical intervention.

Question: What can be done for her? The next plan?

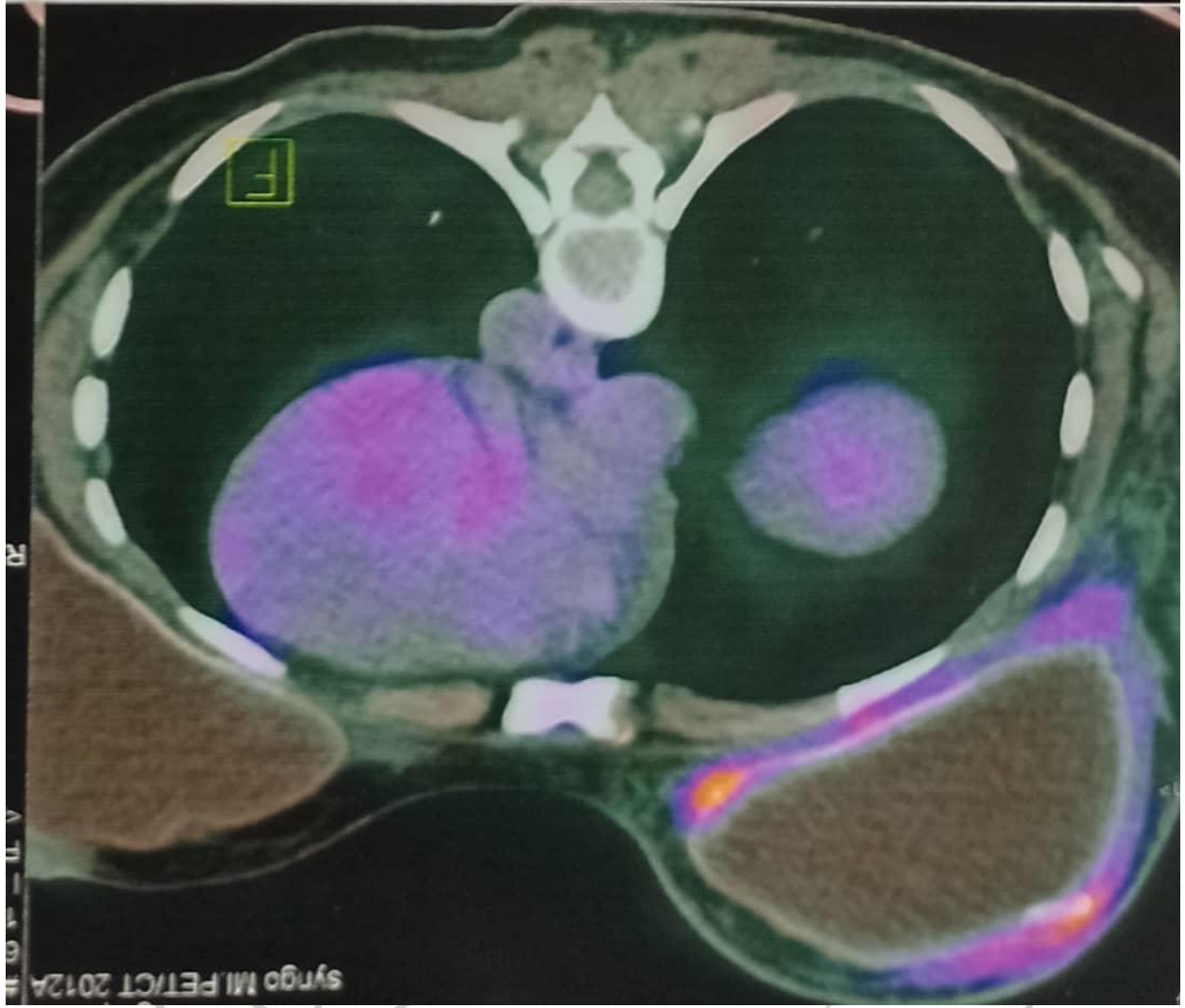
Recommended tests: Since documents review revealed multiple visible suspicious internal mammary and supraclavicular lymph nodes, it's necessary to have full evaluation of thyroid. also new restaging of disease is prudent before any surgical intervention.

considered plan: Return to multidisciplinary joint after them.

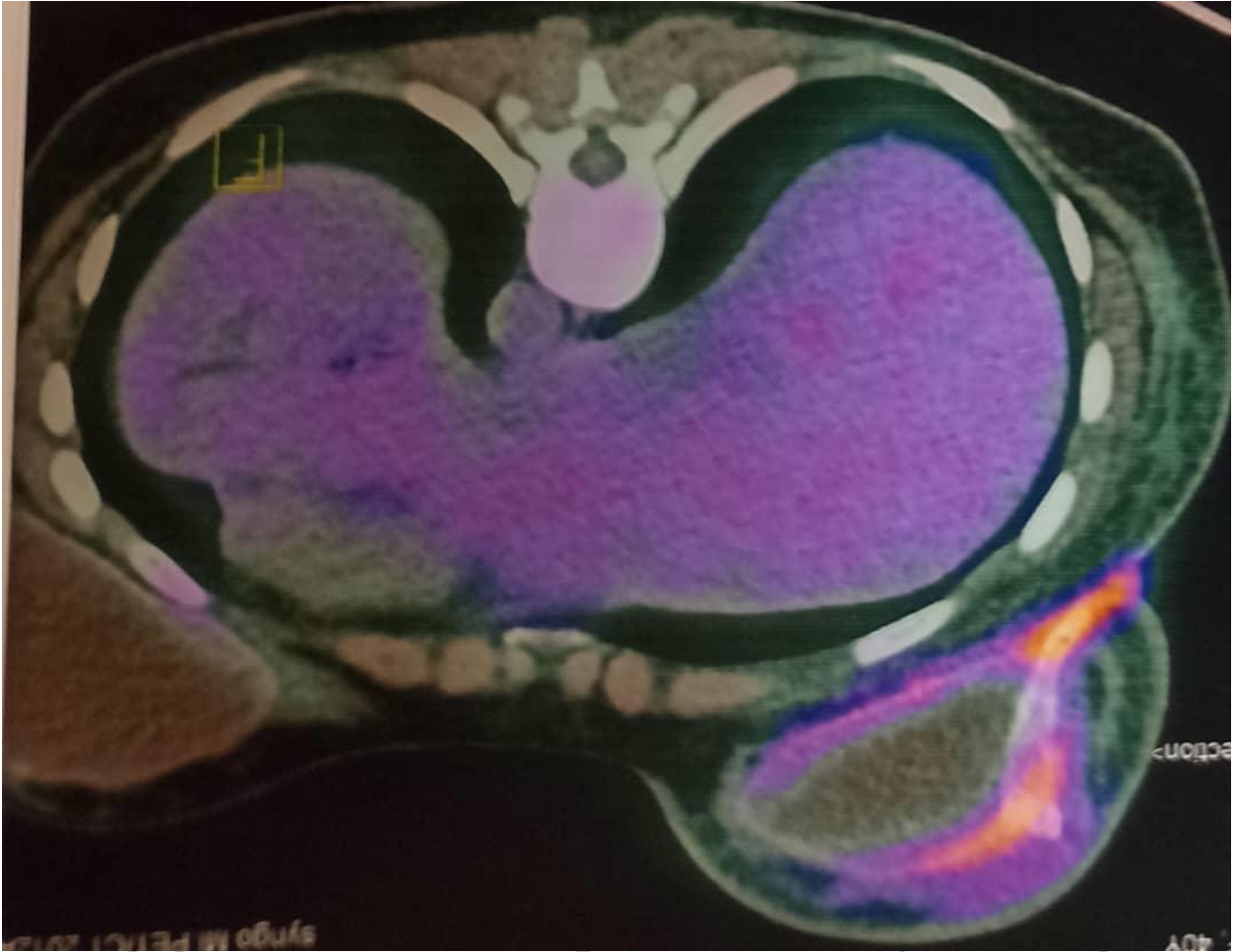




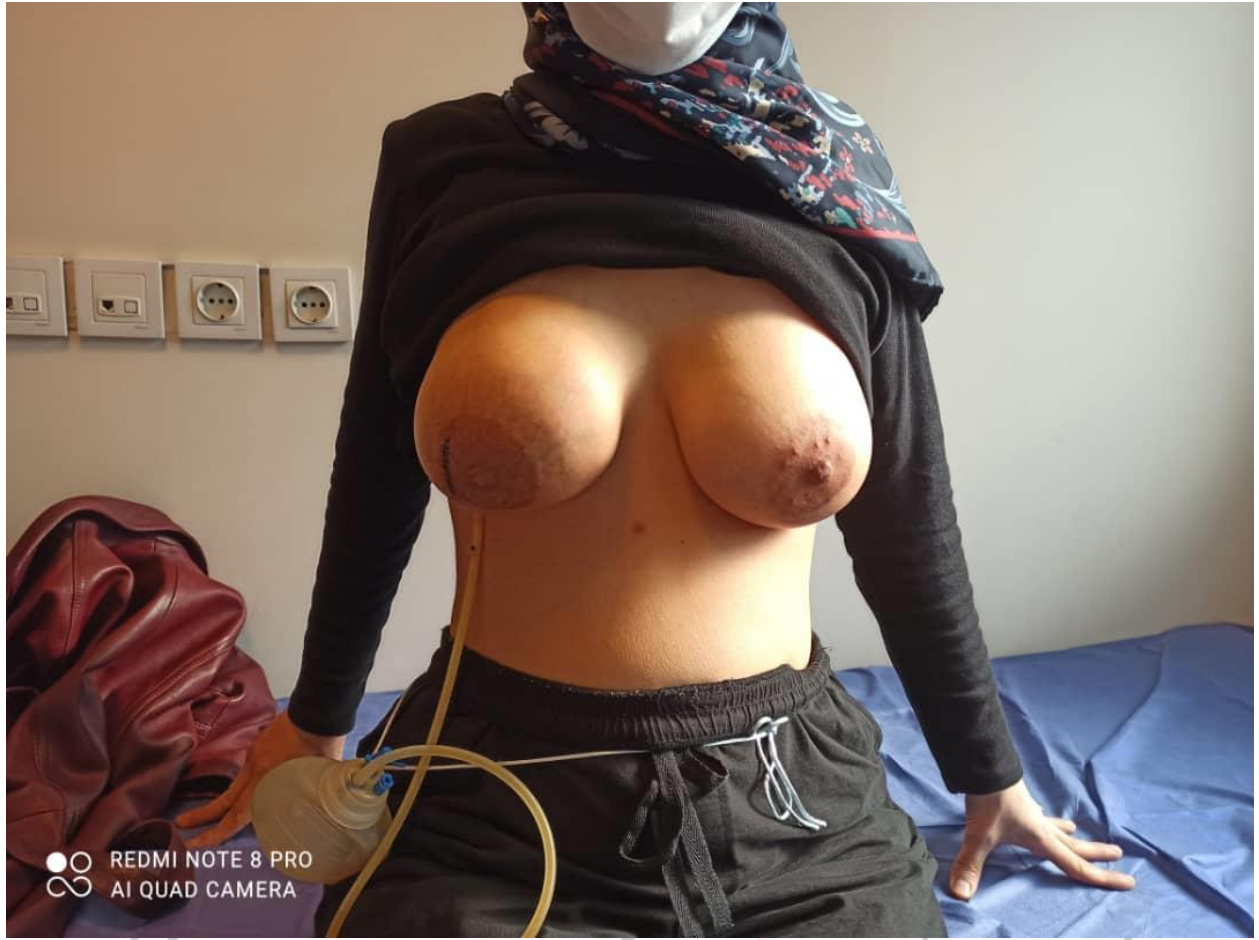east Disease Research Center



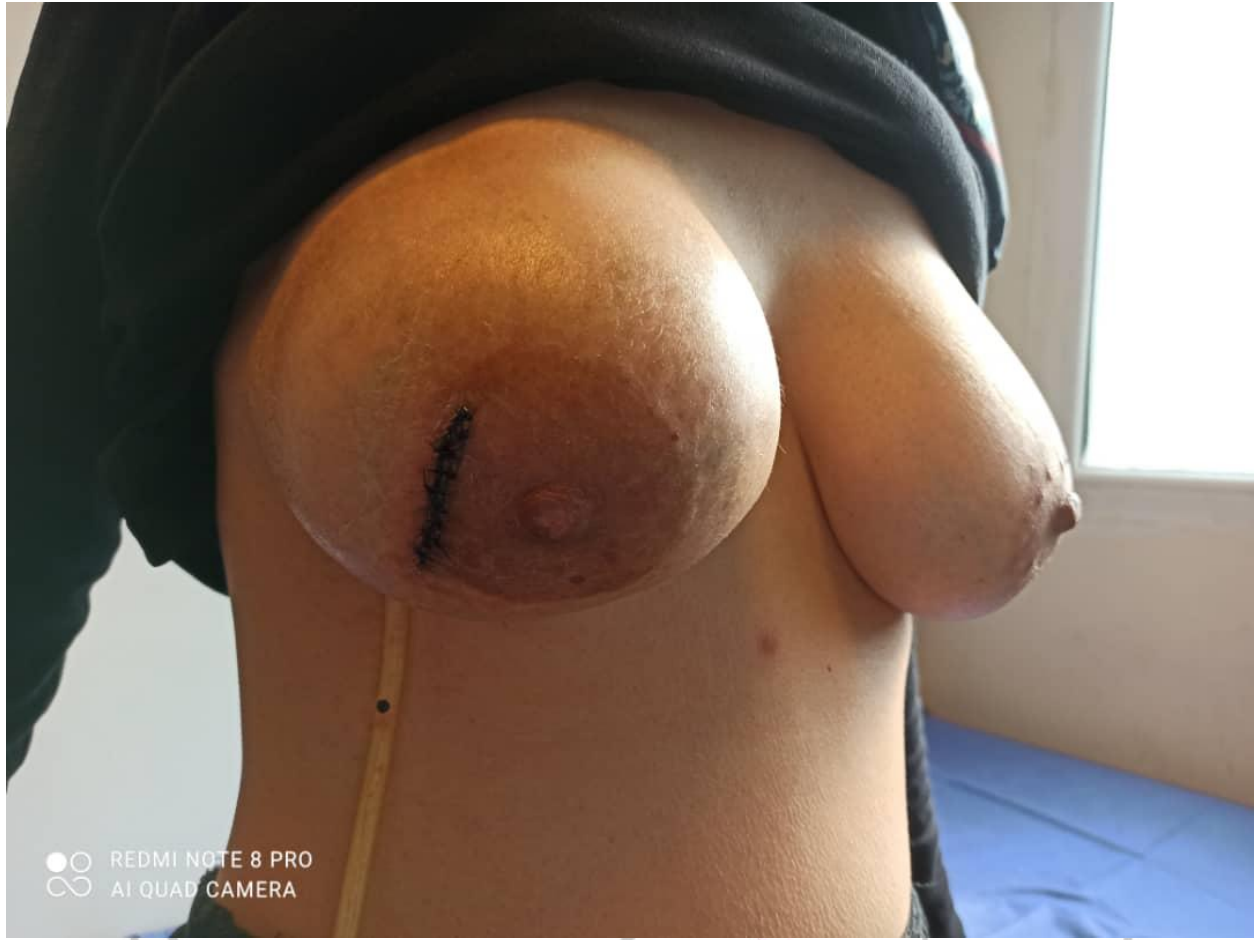Breast Disease Research Center



Breast Disease Research Center



Breast Disease Research Center



Breast Disease Research Center