

**Date:** 2020/12/26; 06/10/1399

**Patient's Name:** Kh.Kh.M

**Responsible Physician:** Dr. Mashayekhi

**Patient presentation:**

- 57years – perimenopausal.

- Presented with palpable Right breast masses.

-Ultrasound: BIRADS 4. Two masses.8o'clock mass spiculated 22mm. 10 o'clock well defined mass 9 mm.

Mammography: BIRADS 4(round spiculated mass at deep portion)

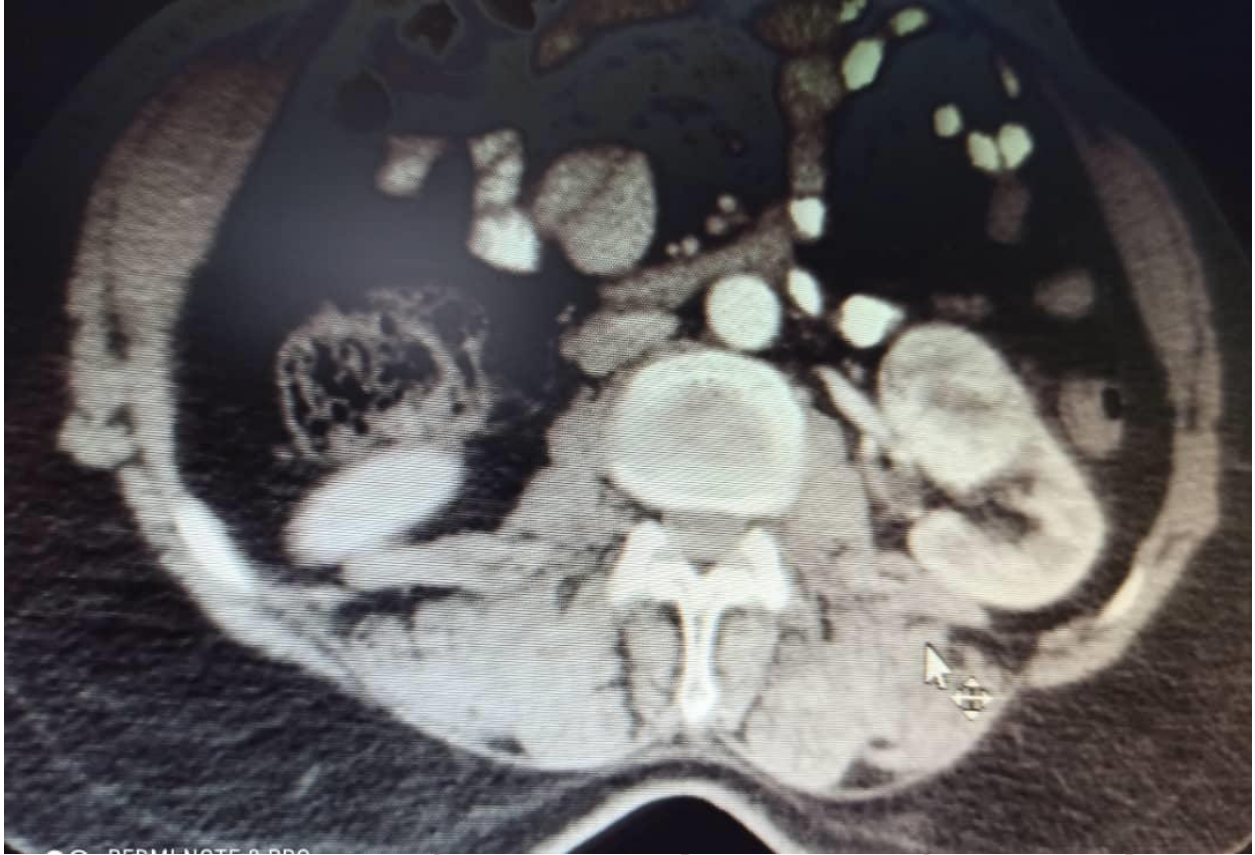- Core needle biopsy: IDC; ER+; PR+; HER2-; Ki67 35%

- Metastatic work up revealed: Some nodules up to 15 mm in right thyroid lobe, some calcified subpleural nodules up to4mm in Left lower lobe, some hypodense lesions up to20 mm in liver between segment 3 and 4, Hyperenhancing42 mm mass with internal necrosis suggesting left Renal cell carcinoma

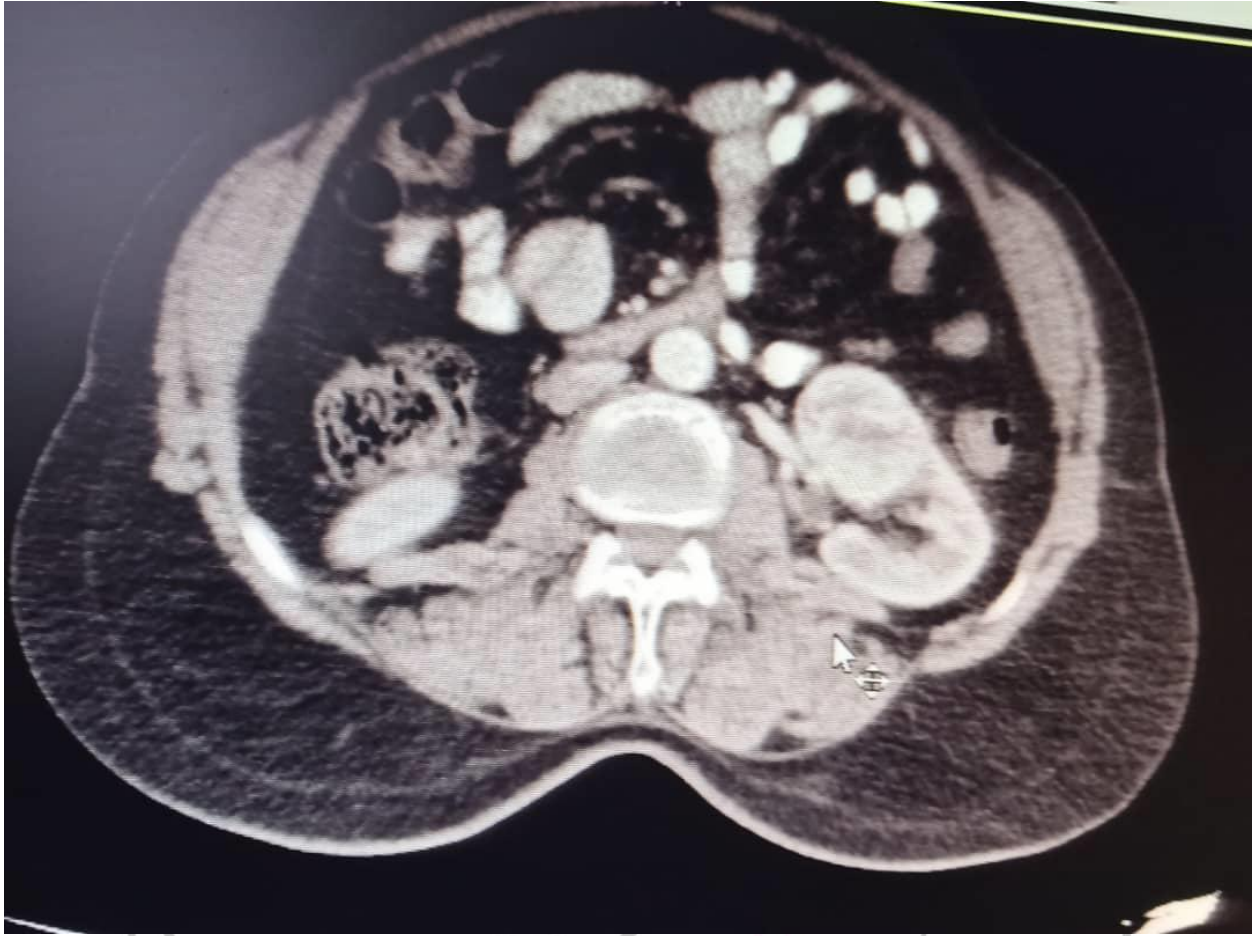
**Question:** How is the plan of treatment?

**Recommended tests:** 1-Dynamic MRI of abdomen & pelvis.2- Thyroid sonography.

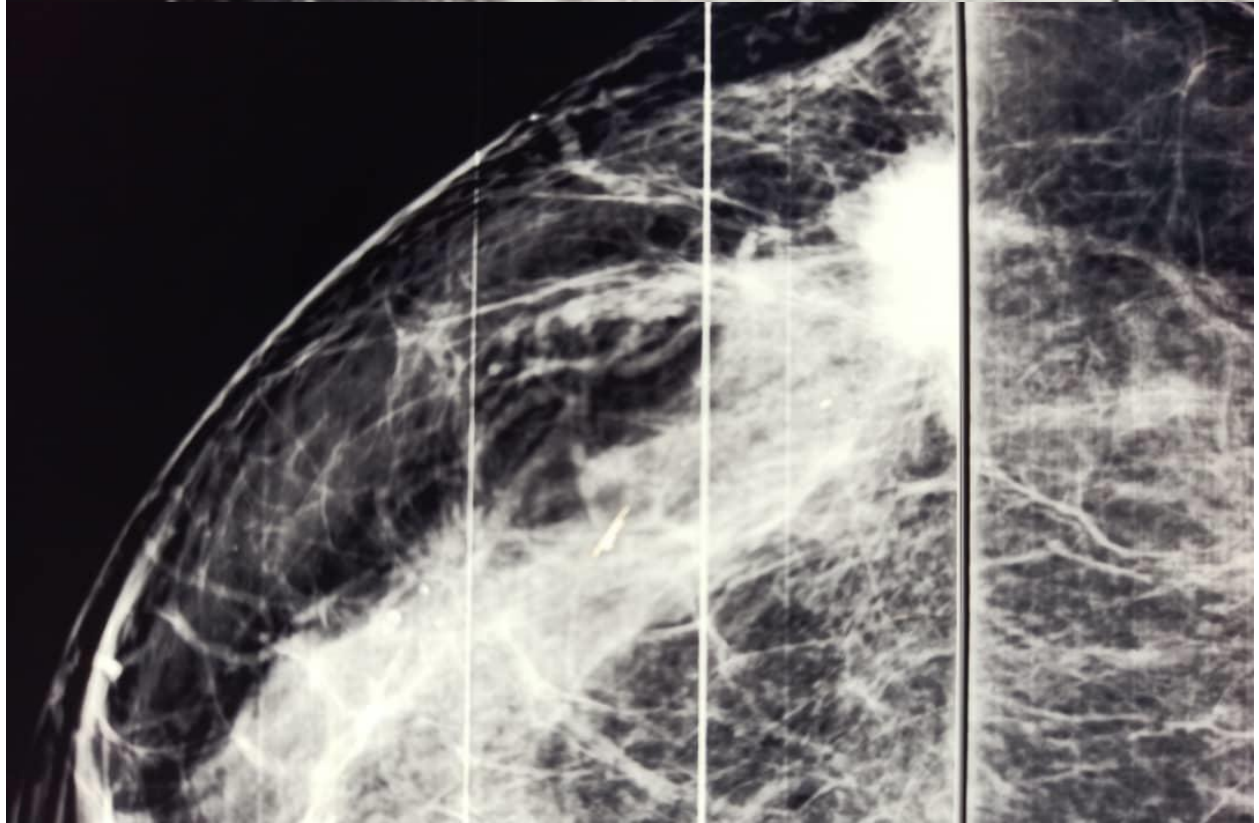
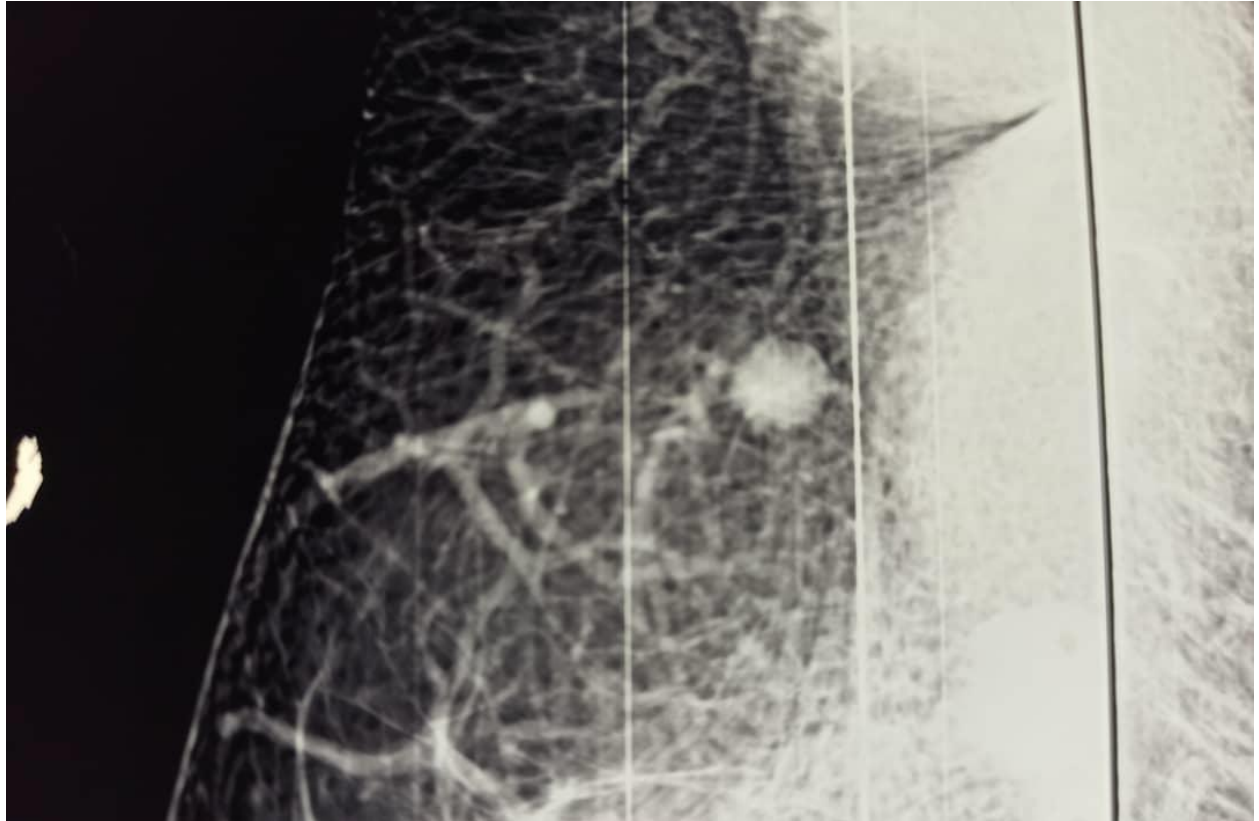
**Considered plan:** Simultaneous surgical intervention for breast and kidney.



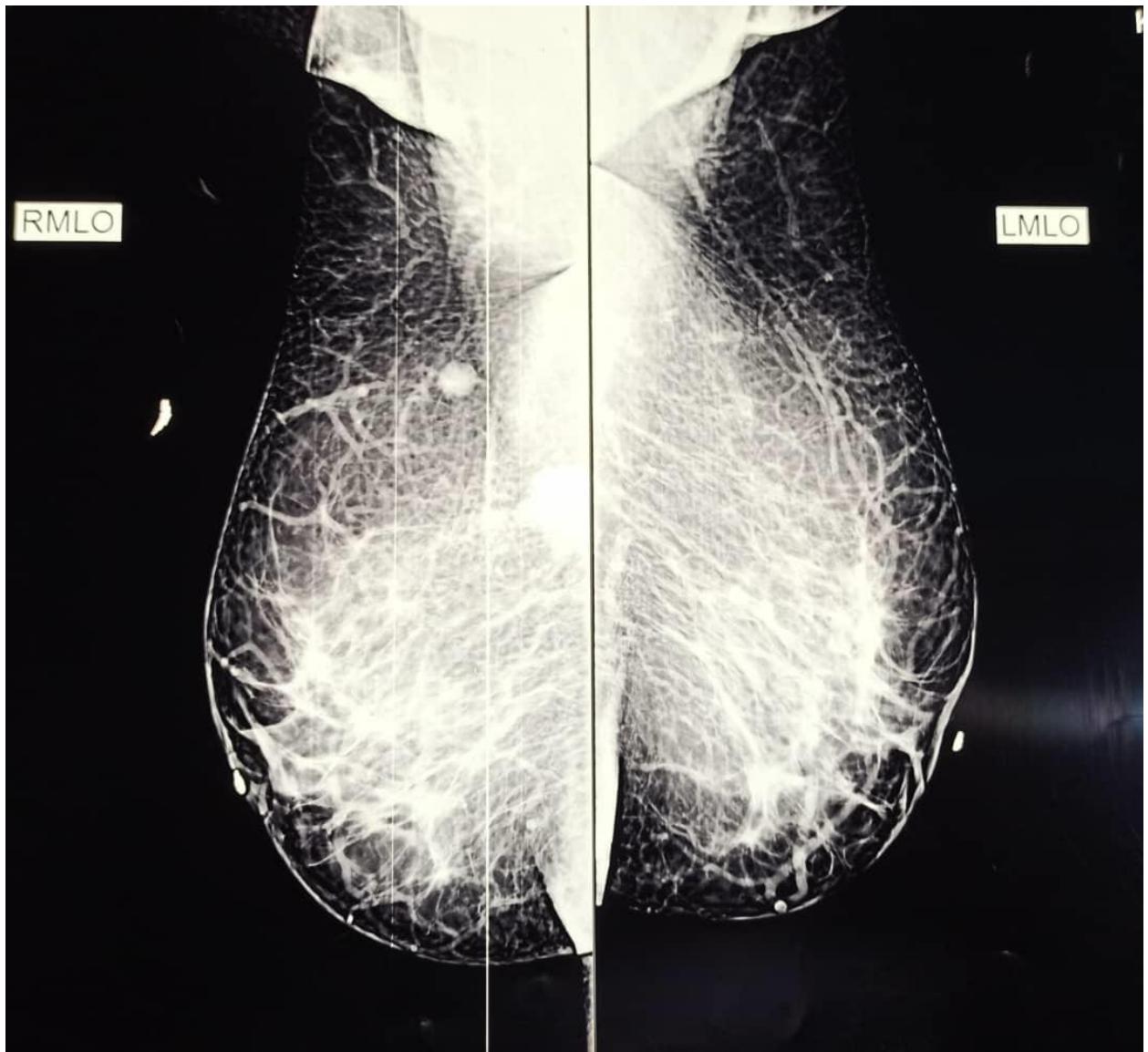
Breast Disease Research Center



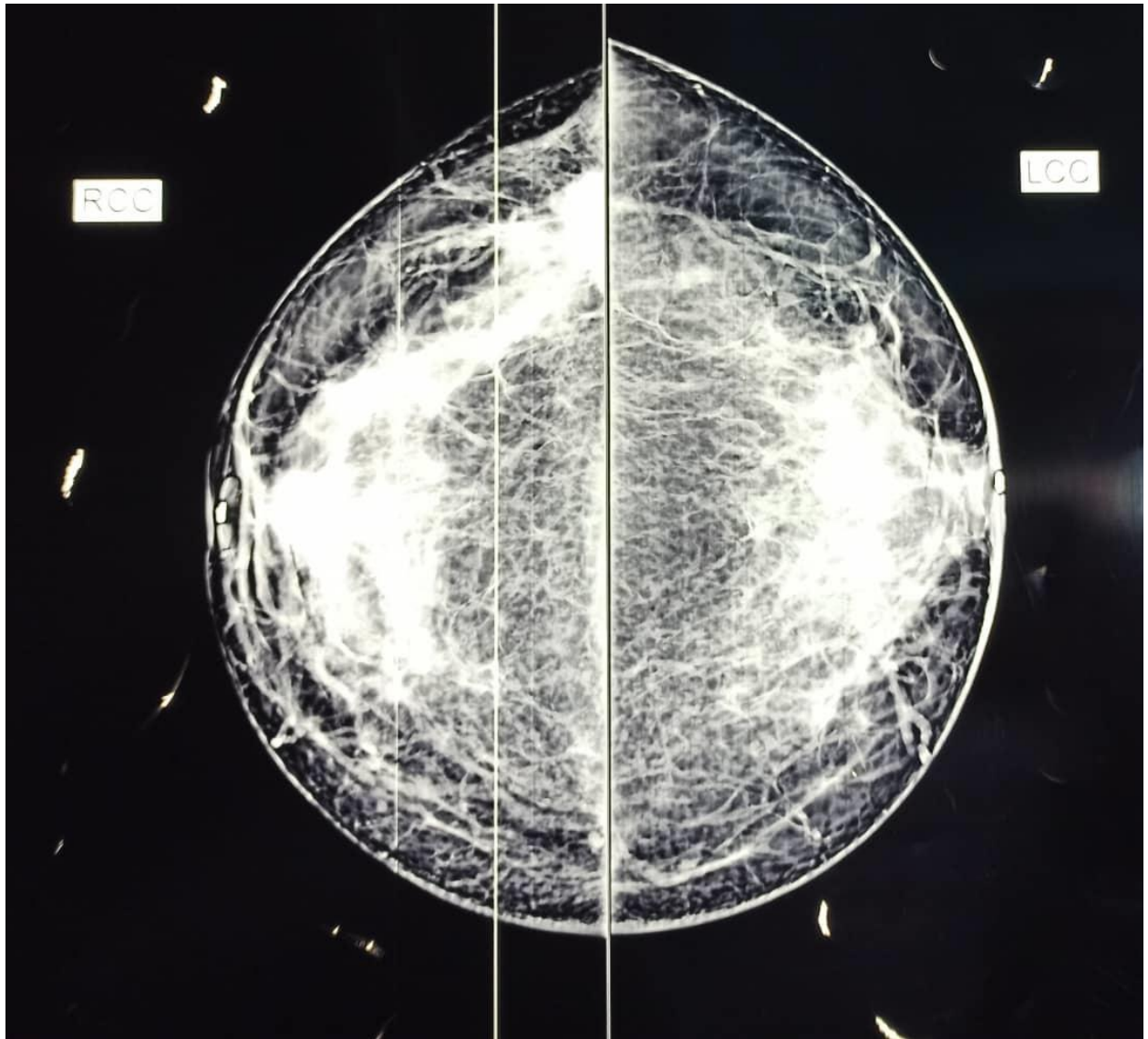
Breast Disease Research Center







Breast Disease Research Center



Breast Disease Research Center