

**Date:** 2020/12/12; 22/09/1399

**Patient's Name:** F.S

**Responsible Physician:** Dr.Omranipour

**Patient presentation:**

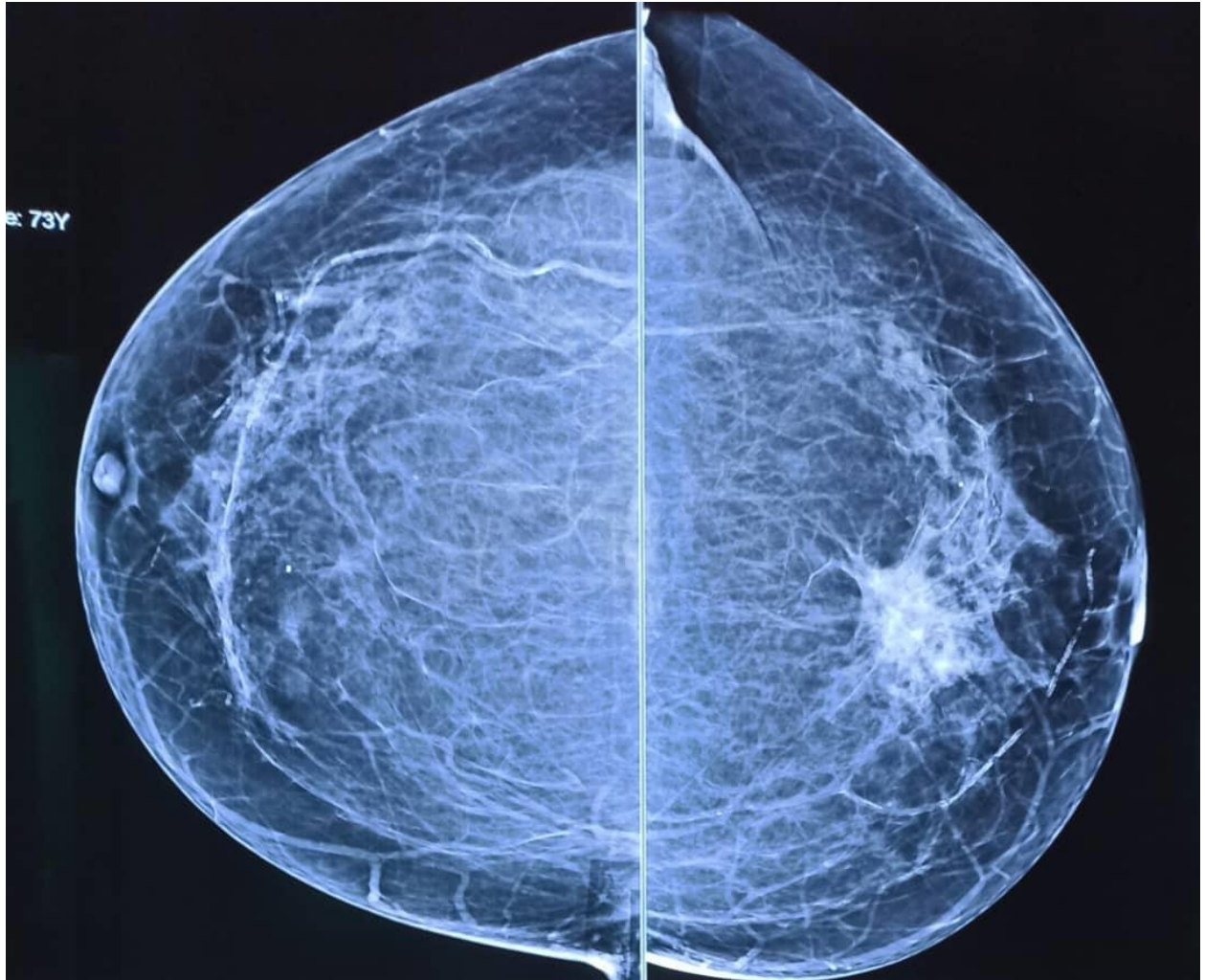
- 73years – positive family history (her daughter)
- Presented with left breast mass.
- Mass size 22mm in sonography: BIRADS 5 with no suspicious lymph nodes.
- Mass Core Needle Biopsy: IDC; G1; ER+; PR +; HER2 -; Ki67 8-10%
- Bone scan: Compression fracture in T12, suspicious for Metastasis
- Abdominal Spiral CT scan: 15 mm hypo vascular mass in segment 3 liver so biopsy recommended & 24 \*12 mm ill-defined mass lesion in left adrenal gland suspicious for Metastasis.

**Question:** 1-CT review? Is it adrenal metastasis?

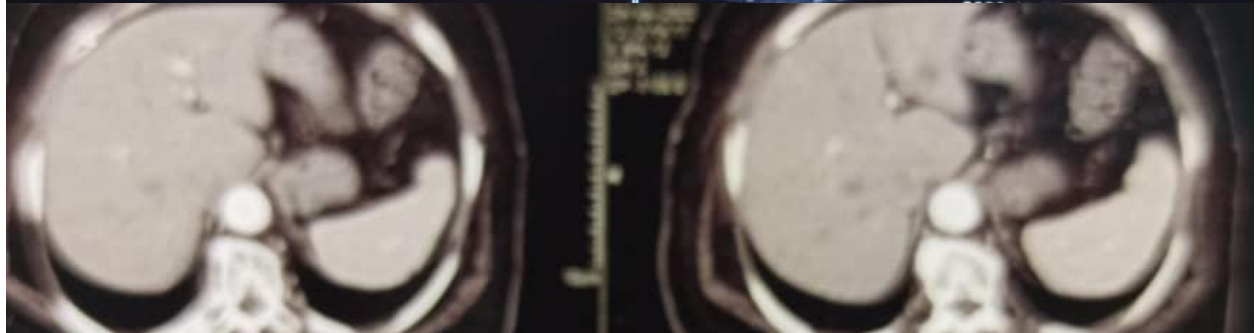
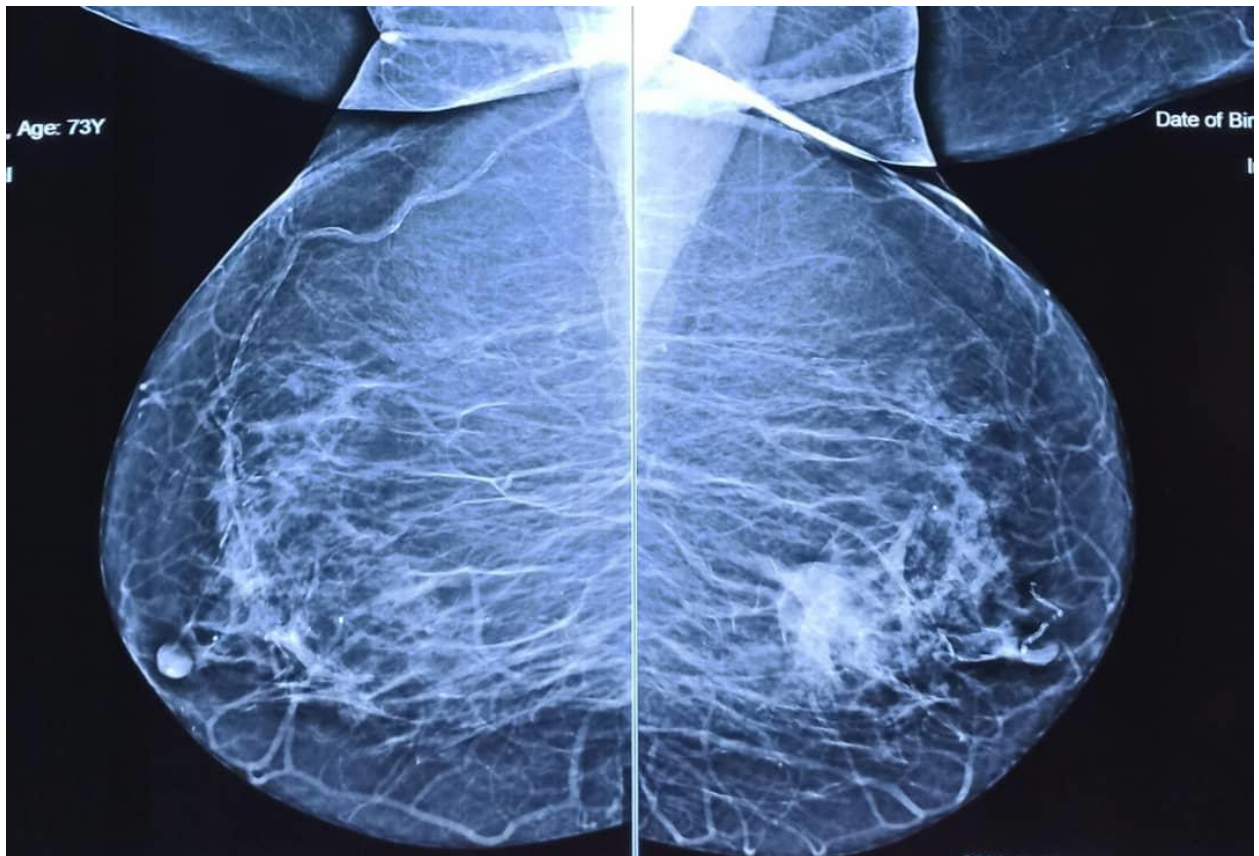
2-Biopsy of it should be performed??

**Recommended tests:** Abdominal MRI with and without intravenous gadolinium contrast.

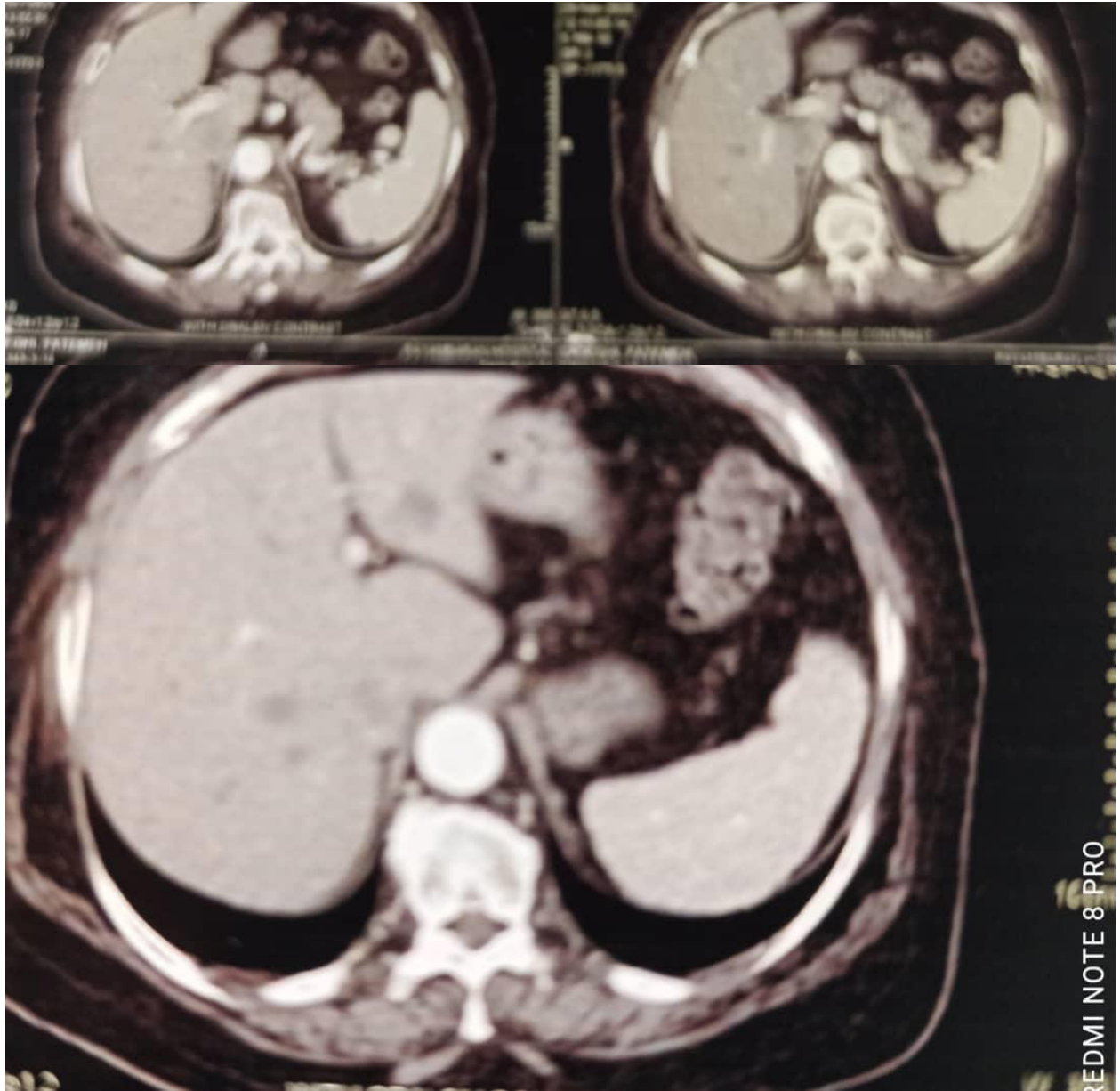
**Considered plan:** representation in multidisciplinary team afterward.



Breast Disease Research Center



Breast Disease Research Center



East Disease Research Center