

Date: 22 June 2019 . 98/4/1.

Patient's Name: T.A.

Responsible Physician: Dr.Mir.

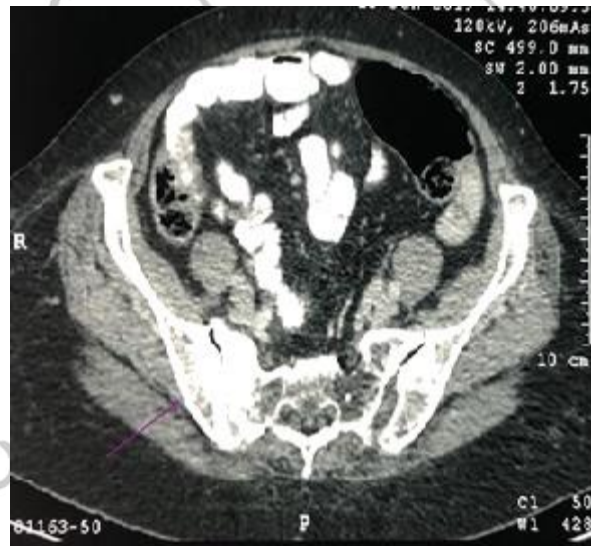Patient Presentation:

-A 58 year old female with past history of rectal cancer and pelvic RT 7 years ago, presented with left breast cancer(ER+, HER2-) and underwent NAC.

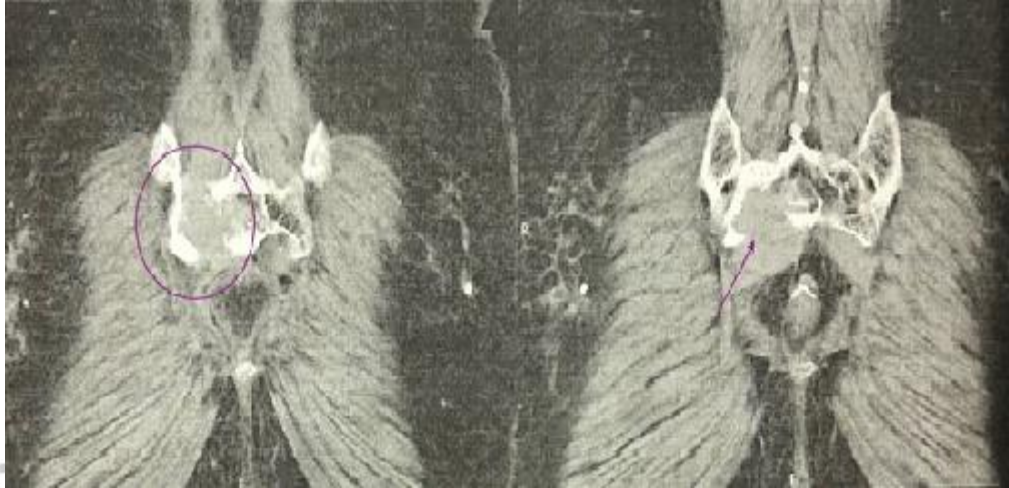
-During chemotherapy she presented with pelvic pain and Pelvic MRI revealed 50 mm right sacroiliac lytic lesion. The lesion was stable in repeated bone scan after chemotherapy.

Question: Plan?

Recommended Plan: Pelvic Radiation.



Abdominopelvic CT scan which shows right iliac sclerotic lesion.



Pelvic MRI which shows right iliac lesion.

