

**Date:** 25 May 2019 . 98/3/4.

**Patient's Name:** Z.P.

**Responsible Physician:** Dr.Sedighi.

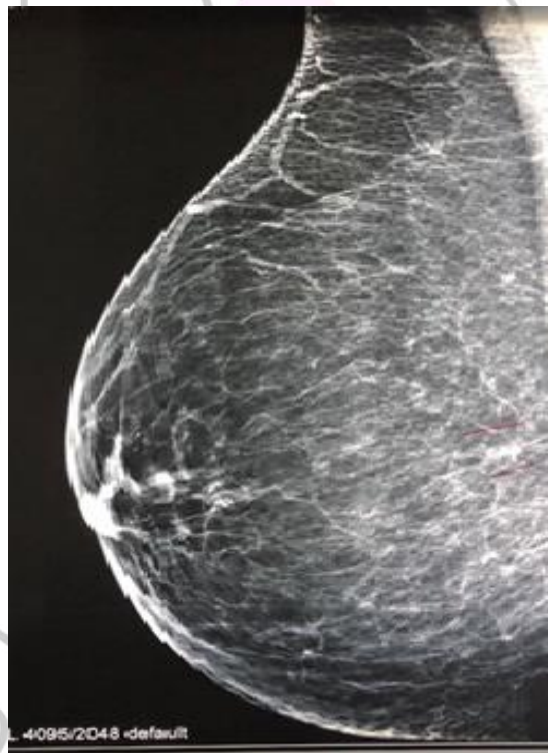
**Patient Presentation:**

-A 52 year old female with past history of left breast cancer 5 years ago underwent mastectomy (T=2cm, G2, no LN involvement, ER+, HER-) and then administered tamoxifen.

-In her follow up mammogram, suspicious lesion in UOQ of right breast was reported (B4b).

**Question:** Regarding mammography report, what should be done? Can tamoxifen be discontinued?

**Recommended Plan:** Breast MRI and stereotactic biopsy of the lesion should be done; Tamoxifen can be continued.



Mammogram of the patient which shows UOQ suspicious.