

Date: 18 May 2019 . 98/2/28.

Patient's Name: S.A.

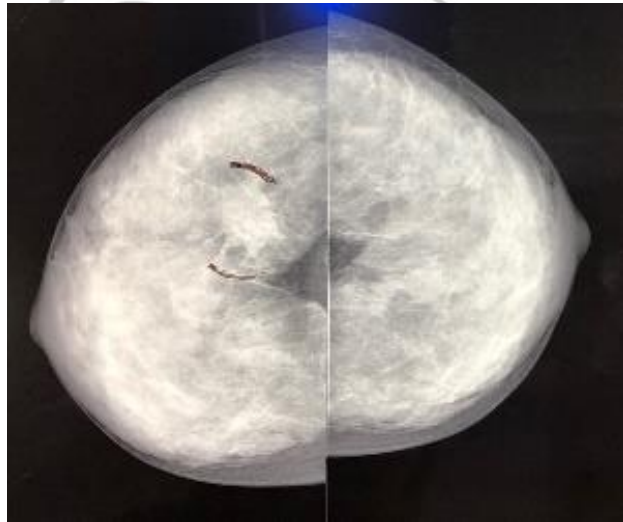
Responsible Physician: Dr.Omranipour.

Patient Presentation:

-A 35 year old female presented with right breast LOQ and 9 o'clock masses. CNB of both masses was done and pathology review showed IDC(ER+, PR+, HER-, Ki67 15%) and fibroadenoma respectively. In mammography she has dense breasts.

Question: Regarding mammography, is BCS possible?

Recommended Plan: Digital mammography and breast MRI should be done.



Mammography of the patient which shows dense breasts and right LOQ spiculated mass.

Breast Disease Research Center