

Date: 11 May 2019. 98/2/21.

Patient's Name: P.B.

Responsible Physician: Dr.Elahi.

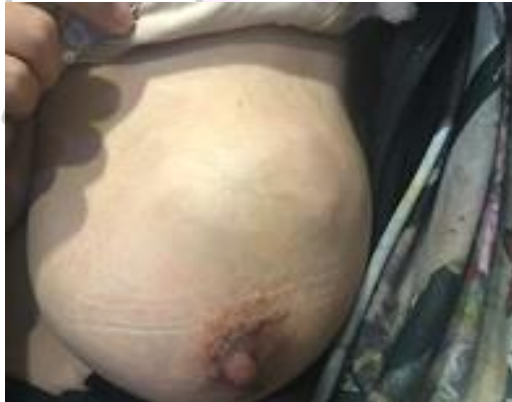Patient Presentation:

-A 43 year old female presented with left breast mass since 15 years ago (FNA: fibroadenoma)with recent growth. In physical examination, there was a 10*8 cm lobulated mass in upper central part of left breast.

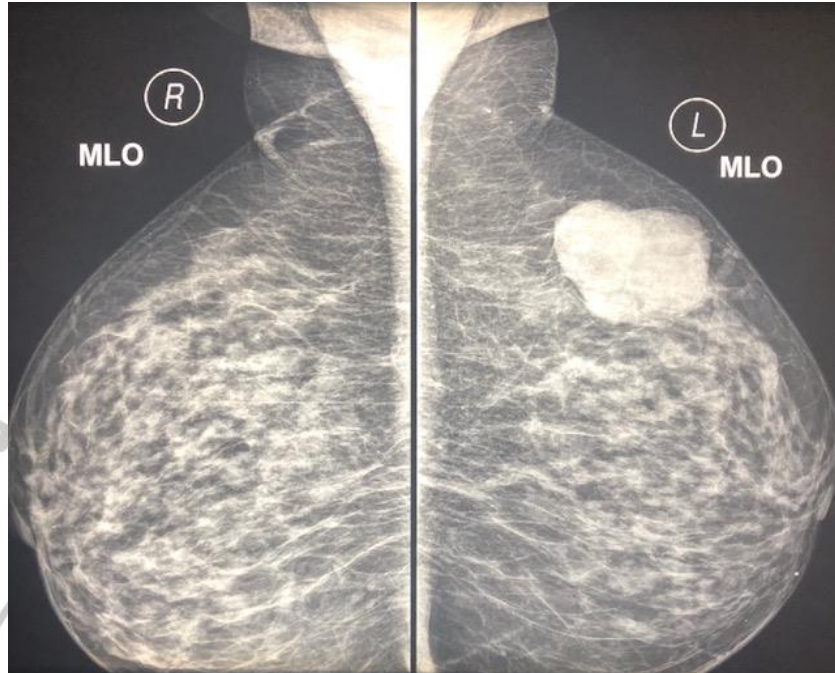
-Mammography reported a 50mm lobulated mass with regular borders in UOQ of left breast, and US showed a 47mm solid cystic mass in 1 o'clock of left breast. CNB was done which reported metaplastic carcinoma or high grade malignant phyllodes tumor (Ki67:55%).

Question: NAC or surgery?

Recommended Plan: Surgery (MST+SLNB).



Patient's left breast mass.



Mammogram which shows a 50mm lobulated mass with regular borders in UOQ of left breast.

Breast Disease Research Center