

**Date:** 1 Feb 2019. 98/11/12.

**Patient's Name:** M. B.

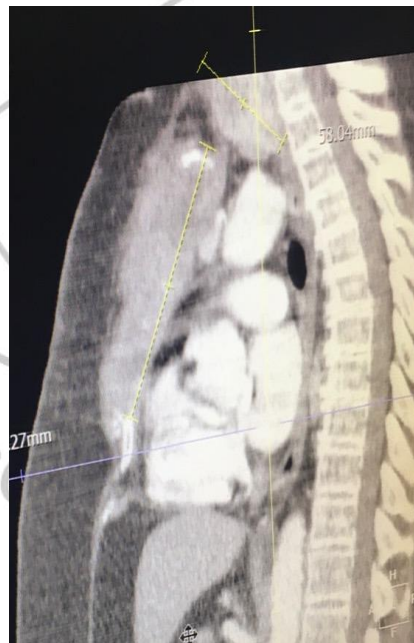
**Responsible Physician:** Dr. Omranipour

**Patient Presentation:**

- A 54year old female with left breast cancer 2years ago
- Neo-adjuvant: chemotherapy 8 courses
- Surgery: MRM
- Pathology: multiple foci of residual tumor, 1 area of extra nodal involvement
- Immunohistochemistry: ER+, PR+, HER2 3+, Ki67 70%
- Adjuvant treatment: Herceptin, radiotherapy, aromasine
- Now thyroid nodules, history of right side lobectomy
- Chest CT scan: lytic lesion of sternum, enlarged hilar and mediastinal lymph nodes, left thyroid lobe 30\*40mm with heterogenous attenuation
- FNA of right lobe: PTC
- Pathologic review: metastatic carcinoma

**Question:** what is the next plan?

**Recommended Plan:** core biopsy of sternum and thyroid



Metastasis in sternum