

Date: 25 Jan 2019. 98/11/5.

Patient's Name: H. F.

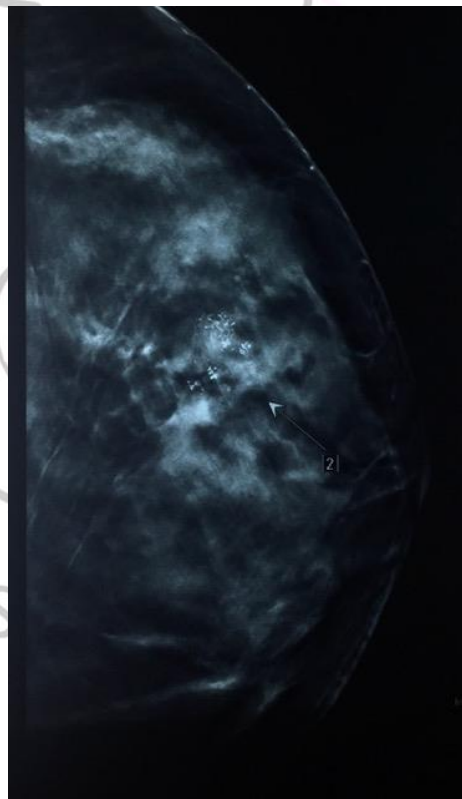Responsible Physician: Dr. Omranipour

Patient Presentation:

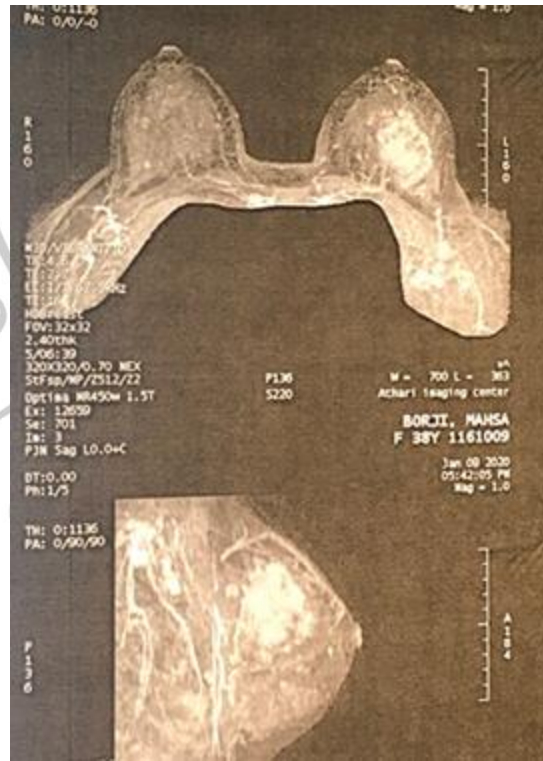
- A 65year old male with left nipple mass
- Biopsy: IDC grade II+ Pagetoid epidermal extension
- Immunohistochemistry: ER+, PR+, HER2-, Ki67 30-35%
- Surgery: mastectomy+ SLNB
- Pathology: IDC 4mm of nipple+ DCIS sub areolar+ Paget's of nipple+ 4 free lymph nodes
- Pathology review: Paget's of nipple, DCIS

Question: what is the next plan?

Recommended Plan: evaluation of first and second pathology, if sum of tumor sizes is more than 1cm then adjuvant chemotherapy is recommended



Mammography shows diffuse micro-calcification; DCIS



MRI shows segmental non mass enhancement

Breast Disease Research Center