

Date: 5 Oct 2019. 98/7/13

Patient's Name: F. Sh

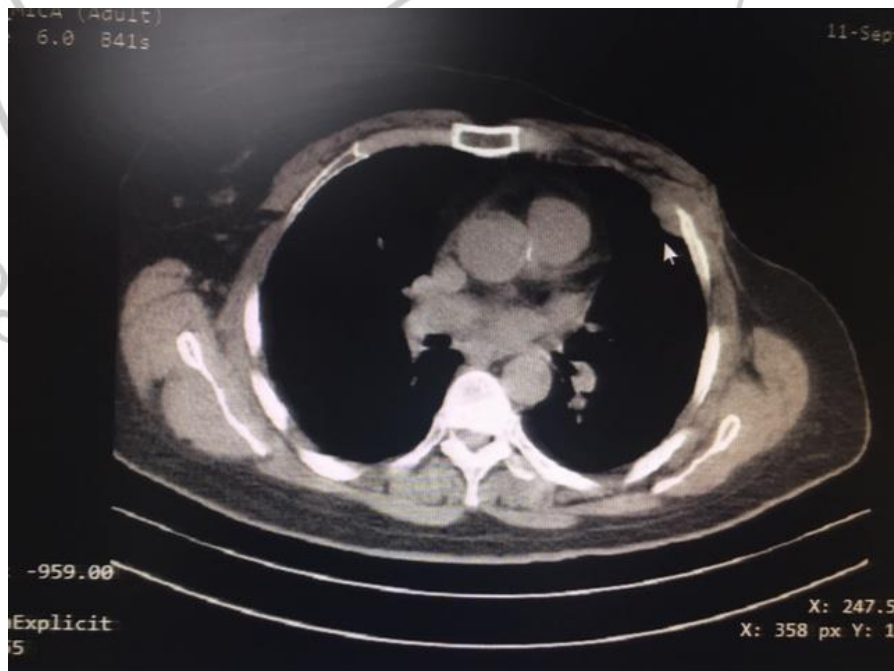
Responsible Physician: Dr. Jalaefar

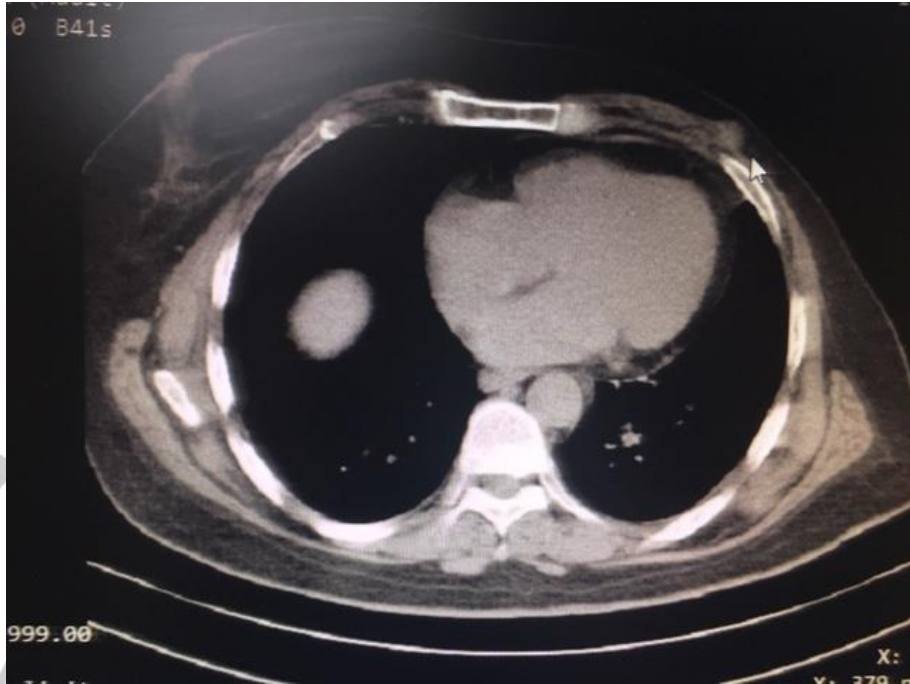
Patient Presentation:

- A61 year old female known case of breast cancer from 4 years ago
- Surgery: modified radical mastectomy
- Pathology: invasive ductal carcinoma
- Immunohistochemistry: not available
- Adjuvant treatment: 4 courses chemotherapy, she did not accept more
- Chest CT scan: soft tissue 16*21 mm in mastectomy site on pectoralis major muscle, another mass 26*15 mm in pectoralis minor muscle that get in to third intercostal space
- Abdominopelvic CT: 4.5 mm lesion between segment 4b and 8
- Bone scan: normal
- Problem: she had local recurrence 2 times, now she has again

Question: What is the next plan?

Recommended Plan: Surgery and chemotherapy after, IHC





Local recurrence in mastectomy site

Breast Disease Research Center