

Date: 2018/12/15

Patient's Name: M.M

Physician: Dr. Mohagheghi

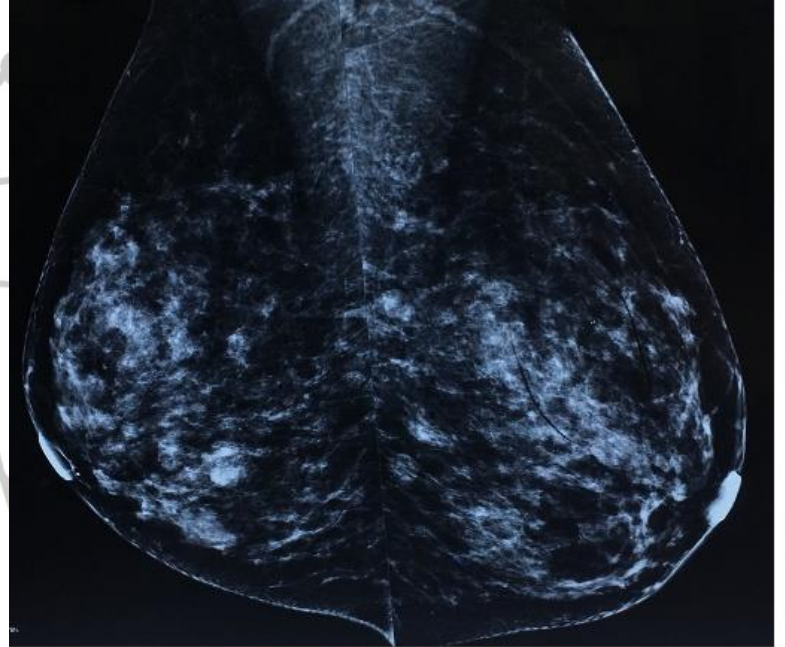
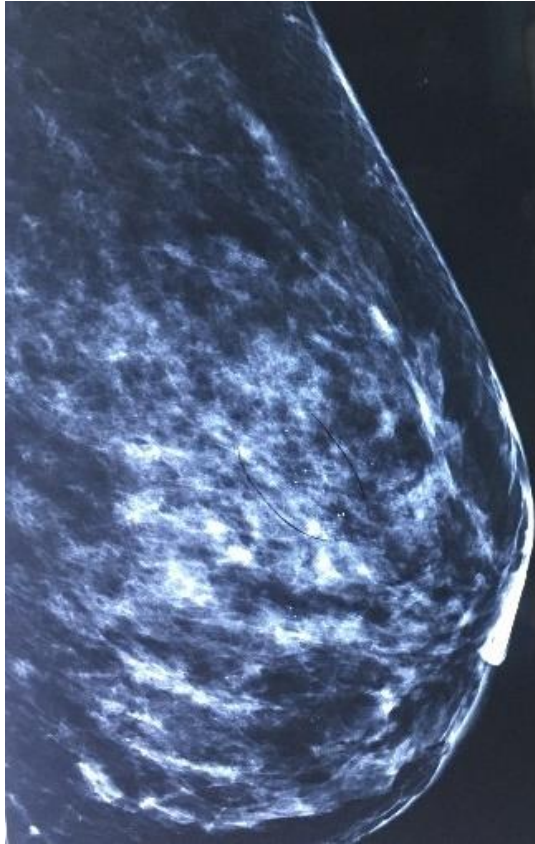
Patient presentation:

- 50 years/ Family history + (Aunt and her mother's cousin)
- She had been under observation due to her family history since 17 years ago
- A new microcalcification was found in her left breast, BIRADS 4c in mammography (4/2018)
- Vacuum assisted biopsy done, result: atypical ductal hyperplasia
- Followed by surgical excision, pathology compatible with fibrocystic changes and adenosis
- Recent MRI (10/2018) : Suspicious lesions (BIRADS 4) at the site of surgery

Question: plan?

Recommended tests:

Recommended plan: Re-biopsy or prophylactic surgery



Breast Disease Research Center