

Date: 2018/11/17

Patient's Name: P.F

Responsible Physician: Dr.Omranipour

Patient presentation:

50 years, Female, Negative family history

History of Right breast mass

Core Needle Biopsy result: Invasive ductal carcinoma, Grade 2, Lympho-vascular invasion - ER PR + (diffuse with strong intensity)HER2 - Ki67:18- 20%.

Abdominal CT Scan:33*25 exophytic mass in mid portion of left kidney highly suggestive of second primary lesion or Renal Cell Carcinoma and large uterine mass.

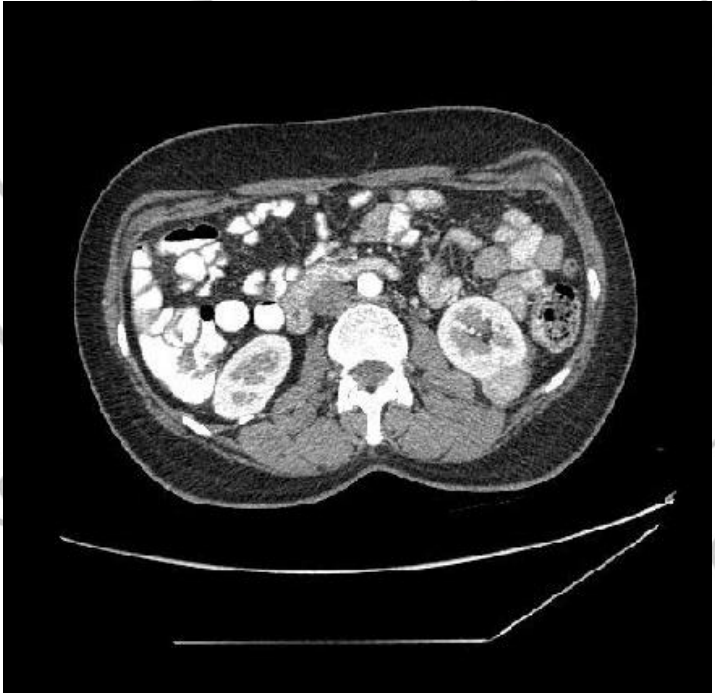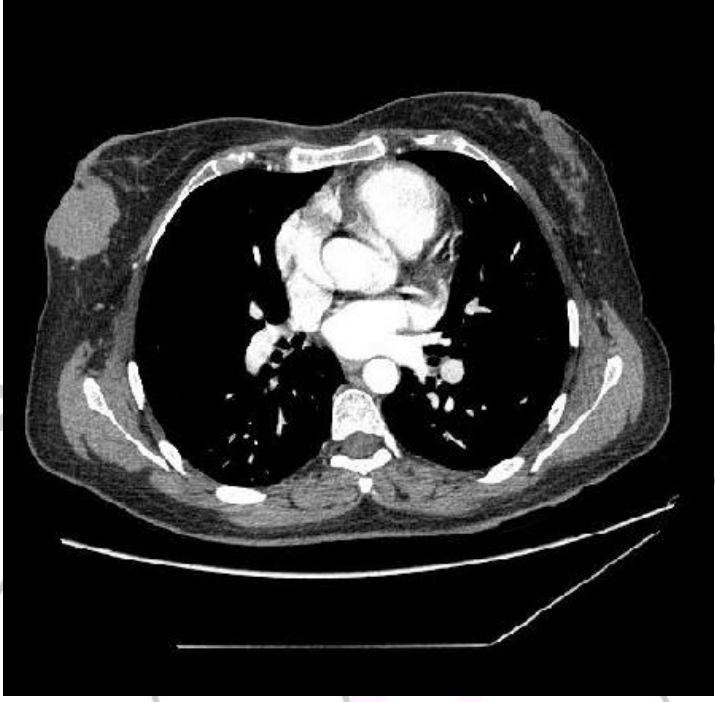
She underwent Modified Radical Mastectomy & partial Nephrectomy simultaneously. Breast pathology: Invasive ductal carcinoma , 5*5cm,Grade 2 , Lympho-vascular invasion +,Margins free, 6/15 Lymph Nodes involved .

Renal pathology: 3.5 cm, spindle cell neoplasm, tumor extended to margins .IHC: SMA+, Desmin+,NSE+,Ki67 10%. Ckit -, DOG1 -,CD99-, WT1 -,S100 -,CK - ,EMA -Consistent with low grade Leiomyosarcoma

Question: Plan?

Recommended tests:-Abdomino-pelvic MRI to rule out uterine sarcoma

Recommended plan: Initiation of breast Adjuvant chemotherapy



ستان

مركز
تحقیق

Breas

ch Center